



Received: 2015.10.11
Accepted: 2015.12.15
Published: 2016.07.19

Authors' Contribution:

- A** Study Design
- B** Data Collection
- C** Statistical Analysis
- D** Data Interpretation
- E** Manuscript Preparation
- F** Literature Search
- G** Funds Collection

Evaluation of the Course of the Inferior Alveolar Canal: The First CBCT Study in an Iranian Population

Sanam Mirbeigi^{1ABCD}, Maryam Kazemipour^{2ACDEF}, Leila Khojastepour^{3EG}

¹ Department of Oral and Maxillofacial Radiology, Dental School, Shahid Sadoughi University of Medical Sciences, Yazd, Iran

² Department of Endodontics, Dental School, Shahid Sadoughi University of Medical Sciences, Yazd, Iran

³ Department of Oral and Maxillofacial Radiology, Dental School, Shiraz University of Medical Sciences, Shiraz, Iran

Author's address: Sanam Mirbeigi, Department of Endodontics, Dental School, Shahid Sadoughi University of Medical Sciences, Yazd, Iran, e-mail: dr.kazemipour@gmail.com

Background:

The frequent anatomical variations of the inferior alveolar nerve (IAN) course should be considered prior to any treatment in this area. The aim of this study was to evaluate the course of the inferior alveolar canal (IAC) as it appears in the archived CBCT images of the mandible.

Material/Method:

This cross-sectional study evaluated a sample of 156 CBCT examinations. The pattern of the IAC was evaluated and the prevalence of different patterns according to age and gender were recorded. In order to find the frequency of mandibular canal type among different ages, the patients were put into the three age groups (20–29, 30–44 and 45–59). The data were analyzed using Chi-square test and the significance level was set as $p \leq 0.05$.

Results:

Out of 156 patients, 52 canals were straight type, 52 had Catenary type and 52 of them were presented with Progressive descending type. There was not statistically significant difference between two genders ($P=0.092$). According to the type of the IAC course, there was not statistically significant difference between the three age groups ($P=0.32$).

Conclusions:

Cone beam computed tomography is a useful method for precise assessment of the IAC course.

MeSH Keywords:

Anatomic Variation • Cone-Beam Computed Tomography • Mandibular Nerve

PDF file:

<http://www.polradiol.com/abstract/index/idArt/896229>

Background

The location and course of the inferior alveolar canal (IAC) is extremely important in any surgical approaches involving the posterior mandible [1,2]. Therefore, the frequent anatomical variations of the inferior alveolar nerve (IAN) course should be considered prior to any treatment in this area [3].

Studies which recorded the course of the mandibular canal are limited [4]. Olivier [5] found that the mandibular canal passes lingually to the roots of the second and third molars, adjacent to the roots of the first molar and lateral to the roots of the premolars. According to Worthington [6] study, there are 3 different configurations of the mandibular canal as follows: 1) a progressive curve rising from anterior to posterior; 2) a steep ascent from anterior to posterior and 3) a catenary-like canal.

Cone beam computed tomography (CBCT) used different planes for assessment of this anatomic structure that leads to a delicate detection of anatomic variations along the IAN course [3].

The aim of this study was to evaluate the morphological course of the human mandibular canal in the CBCT images of the mandible.

Material and Methods

All the experimental procedures in this study were approved by the Ethics in Research Committee of the Shahid Sadoughi University of Medical Sciences, Yazd, Iran. Nine hundred and twenty patients were enrolled in this study between January 2013 and March 2014. They underwent CBCT scans for different dental purposes. Among them only 156 patients met the inclusion criteria.

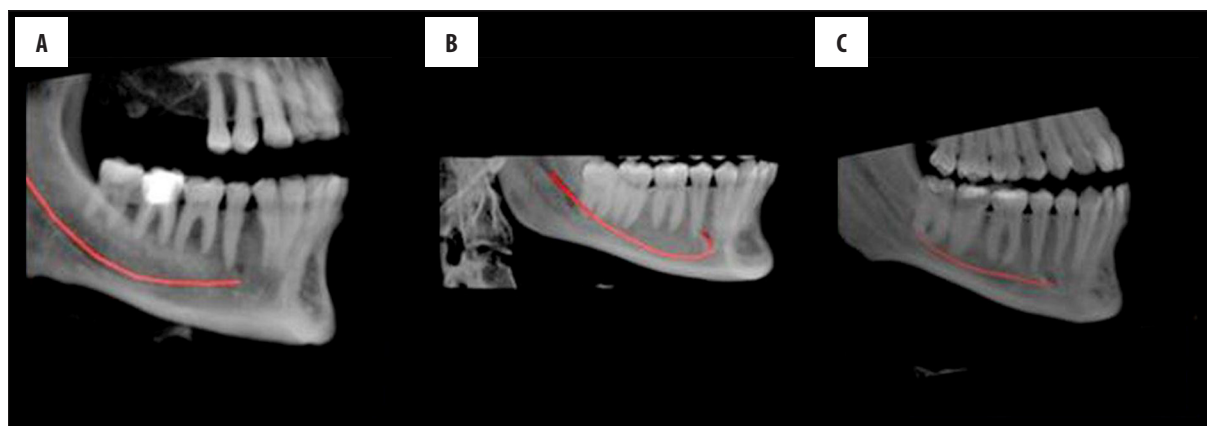


Figure 1. X-ray images of the mandibles showing three types of the mandibular canal: (A) Catenary, a symmetric elliptic arc (B) Progressive descending, a spoon-shape curve similar to a dissymmetry elliptic arc and (C) Straight type, linear pattern.

Table 1. Frequency of mandibular canal types according to gender.

Canal type Gender	Catenary Number (%)	Progressive descending Number (%)	Straight Number (%)	Total Number (%)
Male	24 (34.8%)	22 (31.9%)	23 (33.3%)	69 (100%)
Female	28 (32.2%)	30 (34.5%)	29 (33.3%)	87 (100%)
Total	52 (33.3%)	52 (33.3%)	52 (33.3%)	156 (100%)

Table 2. Frequency of mandibular canal types according to age group.

Canal type Age group	Catenary Number (%)	Progressive descending Number (%)	Straight Number (%)	Total Number (%)
Male	8 (25.0%)	12 (37.5%)	12 (37.5%)	32 (100%)
Female	27 (32.9%)	24 (29.3%)	31 (37.8%)	82 (100%)
Female	17 (40.5%)	16 (38.1%)	9 (21.4%)	42 (100%)
Total	52 (33.3%)	52 (33.3%)	52 (33.3%)	156 (100%)

The inclusion criteria were considered as the presence of the first and second premolars and molars on both sides of the mandible, and the exclusion criteria as the presence of any pathology (radiolucency that might represent a cyst, tumor or periapical lesion), and fracture, supernumerary or impacted teeth in the region of interest (ROI) which obscure visualization of the mandibular canal.

All CBCT scans were taken with NewTom VGi Scanner (NewTom QR srl, Verona, Italy) in a standard resolution mode (110 kV, voxel size=0.3 mm and field of view ≥6×6 cm). Considering the inclusion criteria, only the CBCT images which had acceptable quality and covered the whole length of the mandibular canal were included in this survey.

The CBCT images were evaluated by an experienced (8 years) oral and maxillofacial radiologist on a 27-inch flat-panel color active matrix TFT medical display (Nio Color 3 MP, Barco, Kortrijk, Belgium) under dim lighting conditions. The mandibular canal course was traced and highlighted

in the panoramic reconstructed images. After producing the ray cast images in the sagittal plane, by the aid of NNT software tool (ver. 4, New Tom QR srl), the mandibular canal course was located and marked. Then, the pattern of the mandibular canal course was categorized according to the Worthington study (Figure 1) [6]. The data were analyzed using SPSS software (SPSS version 15.0, SPSS, Chicago, IL, USA) and Chi-square test. The significance level was set at $P \leq 0.05$.

Results

Of 920 available CBCT scans, only 156 (69 male and 87 female) met the inclusion criteria. The age range of those patients was between 20-59 years with the mean age of 36.99 ± 8.53 years. Out of 156 patients, 52 canals (23 male and 29 female) were of Straight type, 52 patients (24 male and 28 female) had Catenary type and 52 of them (22 male and 30 female) were presented with Progressive descending type (Table 1).

In order to find the frequency of mandibular canal type among different ages, the patients were divided into three age groups (20–29, 30–44 and 45–59) (Table 2). Chi-square test revealed that there was a statistically non-significant difference between the three age groups ($P 0.32$). Also, there was no relationship between gender and the pattern of IAN ($P 0.092$).

Discussion

The mandibular canal as a landmark can exhibit important anatomic variations. Inflammatory process, infectious disease and neoplastic, iatrogenic or idiopathic lesions are some causes of this diversity [7,8]. All the dental procedures in the mandibular area such as IAN anesthetic block, tooth extraction, surgical treatment and even root canal therapy may be influenced by this anatomic structure [9,10].

In this study we applied the Worthington's classification for categorization of the course of IAN. Based on the results of this study, the distribution of all the three different patterns (catenary, progressive descending and straight) was equal in the examined ethnic group, while the distribution of the patterns in Ozturk's study were different. Ozturk et al. [4] evaluated the pattern of IAN using dry skulls of an eastern USA population and recorded the catenary-like pattern in almost one-half (51.1%) of the specimens, followed by the progressive descending (36.7%) and straight one (12.2%).

The dry skull method may have some drawbacks such as the presence of different hidden diseases, lack of relevant data such as age and gender or use of inconsistent and anatomically irrelevant landmarks [11–13].

The position of IAN may differ by gender and age [4]. Kwon et al. [14], in their survey evaluated the course of the IAN canal using CBCT. The course of the inferior alveolar canal was measured in relation to the determined points in the sagittal and coronal plane. According to the results of this study, the risk of nerve damage increases as bone is harvested from the anterior to the posterior mandible. Also, the course and position of IAN were not affected by gender.

This finding was in line with the result of our study. In our study the most and the least frequent canal pattern in the male group was recorded as catenary and progressive descending and in the female group as progressive descending and straight, respectively.

The anatomical position of the IAN canal appears to differ by age [4,14]. In this study, we evaluated the IAN course

in three age groups. Straight and progressive descending pattern were the most prevalent pattern in the 20–29 age group. In the 30–44 and 45–59 group the most prevalent category was recorded as straight and catenary, respectively.

There was not any statistically significant difference between the three age groups. Conventional radiography is unsatisfactory for the detection of delicate structures such as IAC [15]. CBCT with a low radiation dose and a higher resolution presented overall satisfactory visibility of the mandibular canal [16–18]. The frequency of mandibular canal detection on CBCT images is higher in comparison to panoramic radiographs [19]. Furthermore, the visibility of the mandibular canal on panoramic radiographs differed according to the course of IAC [20]. The percentage of clearly visible IAC in the spoon-shaped curves was the highest and the lowest in the linear curves.

Liu et al. [21] in a radiographic study classified the course of IAC as linear, spoon-shaped, elliptic-arc, and turning curve. Among the four determined types, type I (a steep ascent) had the smallest curvature, and type IV (turning curve) had the largest variation. Type III was the most common one and type II had the largest curvature.] In the spoon-shaped curves the percentage of clearly visible IACs was the highest and the lowest was observed in the linear curves.[20] The limitations of the applied panoramic images that were assessed in this study in comparison to the volumetric imaging with CBCT with higher levels of accuracy and the ability to visualize in 3D are some reasons for the different results to our study.

Conclusions

We found equal distribution of different courses of IAC in the study group. Various factors such as gender, age, ethnicity and the methods of examination of IAC could affect the obtained results. Therefore, further studies using CBCT with consideration of these interfering factors should be designed in a larger population.

Anatomic variations related to the position and course of IAC could influence different treatment modalities in the mandibular region. Awareness of these variations is of utmost importance in various surgical procedures involving the mandibular area with the probability of damage to IAC.

Acknowledgement

The authors wish to give special thanks to Roqayeh Hakimian for her contributions to the manuscript and Mohammad Hossein Ahmadi for statistical advice.

References:

- Escoda-Francoli J, Canalda-Sahli C, Soler A et al: Inferior alveolar nerve damage because of overextended endodontic material: A problem of sealer cement biocompatibility? *J Endod*, 2007; 33: 1484–89
- Pogrel MA: Damage to the inferior alveolar nerve as the result of root canal therapy. *J Am Dent Assoc*, 2007; 138: 65–69
- Nagadia R, Tay AB, Chan LL, Chan ES: The spatial location of the mandibular canal in Chinese: A CT study. *Int J Oral Maxillofac Surg*, 2011; 40: 1401–5
- Ozturk A, Potluri A, Vieira AR: Position and course of the mandibular canal in skulls. *Oral Surg Oral Med Oral Pathol Oral Radiol*, 2012; 113: 453–58
- Olivier E: The inferior dental canal and its nerve in the adult. *Br Dent J*, 1928; 49: 356–58

6. Worthington P: Injury to the inferior alveolar nerve during implant placement: A formula for protection of the patient and clinician. *Int J Oral Maxillofac Implants*, 2004; 19: 731–34
7. Orhan K, Aksoy S, Bilecenoglu B et al: Evaluation of bifid mandibular canals with cone-beam computed tomography in a Turkish adult population: A retrospective study. *Surg Radiol Anat*, 2011; 33: 501–7
8. de Oliveira-Santos C, Souza PH, de Azambuja Berti-Couto S et al: Assessment of variations of the mandibular canal through cone beam computed tomography. *Clin Oral Investig*, 2012; 16: 387–93
9. Bilecenoglu B, Tuncer N: Clinical and anatomical study of retromolar foramen and canal. *J Oral Maxillofac Surg*, 2006; 64: 1493–97
10. Renton T: Prevention of iatrogenic inferior alveolar nerve injuries in relation to dental procedures. *SADJ*, 2010; 65: 342–50
11. Afsar A, Haas DA, Rossouw PE, Wood RE: Radiographic localization of mandibular anesthesia landmarks. *Oral Surg Oral Med Oral Pathol Oral Radiol Endod*, 1998; 86: 234–41
12. Mraiwa N, Jacobs R, Moerman P et al: Presence and course of the incisive canal in the human mandibular interforaminal region: Two-dimensional imaging versus anatomical observations. *Surg Radiol Anat*, 2003; 25: 416–23
13. Agthong S, Huanmanop T, Chentanez V: Anatomical variations of the supraorbital, infraorbital, and mental foramina related to gender and side. *J Oral Maxillofac Surg*, 2005; 63: 800–4
14. Kwon kH, Sim KB, Lee JM: Evaluation of the course of the inferior alveolar canal in the mandibular ramus using cone beam computed tomography. *J Korean Assoc Oral Maxillofac Surg*, 2012; 38: 231–39
15. Tepper G, Hofschneider UB, Gahleitner A, Ulm C: Computed tomographic diagnosis and localization of bone canals in the mandibular interforaminal region for prevention of bleeding complications during implant surgery. *Int J Oral Maxillofac Implants*, 2001; 16: 68–72
16. Klinge B, Petersson A, Maly P: Location of the mandibular canal: comparison of macroscopic findings, conventional radiography, and computed tomography. *Int J Oral Maxillofac Implants*, 1989; 4: 327–32
17. Lofthag-Hansen S, Grondahl K, Ekestubbe A: Cone-beam CT for preoperative implant planning in the posterior mandible: visibility of anatomic landmarks. *Clin Implant Dent Relat Res*, 2009; 11: 246–55
18. Oliveira-Santos C, Capelozza AL, Dezzoti MS et al: Visibility of the mandibular canal on CBCT cross-sectional images. *J Appl Oral Sci*, 2011; 19: 240–43
19. Angelopoulos C, Thomas SL, Hechler S et al: Comparison between digital panoramic radiography and cone-beam computed tomography for the identification of the mandibular canal as part of presurgical dental implant assessment. *J Oral Maxillofac Surg*, 2008; 66: 2130–35
20. Jung YH, Cho BH: Radiographic evaluation of the course and visibility of the mandibular canal. *Imaging Sci Dent*, 2014; 44: 273–78
21. Liu T, Xia B, Gu Z: Inferior alveolar canal course: a radiographic study. *Clin Oral Implants Res*, 2009; 20: 1212–18