

Computerized Analysis of Digital Photographs for Evaluation of Tooth Movement

Mohammad Hossein Toodehzaeim¹, Maryam Karandish², Mohammad Nabi Karandish³

¹Associate Professor, Department of Orthodontics, School of Dentistry, Shahid Sadoughi University of Medical Sciences, Yazd, Iran

²Assistant Professor, Department of Orthodontics, School of Dentistry, Shiraz University of Medical Sciences, Shiraz, Iran

³Student, School of Mechanical Engineering, Iran University of Science and Technology, Tehran, Iran

Abstract

Objectives: Various methods have been introduced for evaluation of tooth movement in orthodontics. The challenge is to adopt the most accurate and most beneficial method for patients. This study was designed to introduce analysis of digital photographs with AutoCAD software as a method to evaluate tooth movement and assess the reliability of this method.

Materials and Methods: Eighteen patients were evaluated in this study. Three intraoral digital images from the buccal view were captured from each patient in half an hour interval. All the photos were sent to AutoCAD software 2011, calibrated and the distance between canine and molar hooks were measured. The data was analyzed using intraclass correlation coefficient.

Results: Photographs were found to have high reliability coefficient ($P > 0.05$).

Conclusion: The introduced method is an accurate, efficient and reliable method for evaluation of tooth movement.

Key words: Computerized, Digital; Photographs; Measurement; Tooth movement
Journal of Dentistry, Tehran University of Medical Sciences, Tehran, Iran (2015; Vol. 12, No. 3)

✉ Corresponding author:
M. Karandish, Department of
Orthodontics, School of Dentistry,
Shiraz University of Medical Sciences,
Shiraz, Iran

karandishm@sums.ac.ir

Received: 16 August 2014
Accepted: 25 December 2014

INTRODUCTION

Canine retraction is a critical step following the extraction of first premolar teeth for orthodontic purposes. Rate of canine retraction, dental tipping and anchorage loss during tooth movement need to be evaluated.

The most efficient method must be adopted in clinical practice with maximum benefit for the patient. Some methods have been introduced for evaluation of the rate of tooth movement, dental tipping and anchorage loss in different studies. Almost all previous studies have used radiographs such as panoramic view[1], lateral

cephalometric view [2, 3] or intraoral radiography [4] for evaluation of canine angulation.

For measurement of the amount of space closure and evaluation of tooth movement, some researchers used dental casts or preferred photographs of dental casts [2, 4-6]. Lateral cephalometric view has also been used to measure the amount of canine retraction[3]. For measurement of the amount of anchorage loss, some others used dental casts [1] or the photocopies [7, 8].

In more recent studies, we can see the application of intraoral scanner and software pro-

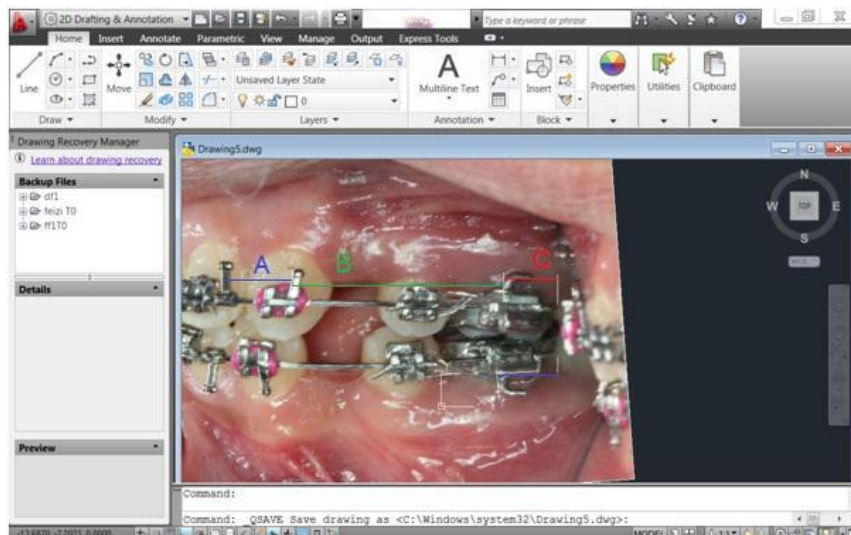


Fig 1. The intraoral photograph imported to the AutoCAD 2010 software

grams such as OrthoCAD for cast analysis and detecting Bolton discrepancy [9, 10].

The purpose of this study was to detect the reliability of the photographic measurement with the AutoCAD software for evaluating canine retraction and suggesting a formula for measuring the amount of canine retraction and anchorage loss with lower risk for patients.

MATERIALS AND METHODS

Eighteen orthodontic patients referred to an orthodontic clinic, under the care of one clinician (M. K) were evaluated. All patients were 13-18 years of age including 10 females and 8 males. They had class I malocclusion with the treatment plan of first premolar extraction. The patients were selected using simple random sampling. Written informed consent was obtained from all patients or their parents.

All patients had pre-adjusted edgewise appliance (Roth prescription, Dentaaurum). Leveling and aligning was completed in all patients and a passive (0.019×0.025) SS preformed arch wire (G&H) was in place for 1 month [1]. Three intraoral mirror image photographs of the right and left upper and lower buccal sides (a total of 72) were taken from each patient. The photos were taken with the teeth in occlusion.

Note that we must have the distal end of the tube fully in our field of view. The interval between three photos was half an hour. All the photos were taken by a single operator based on the ABO instructions with a macro lens:105, diaphragm:32, speed:60, field depth: infinite, and the distance from camera lens to the mirror: 20-25cm recorded individually for each patient (Dental eye camera, Canon).

The lengths of the auxiliary tubes of upper and lower molars were measured by a digital caliper (Shoka Gulf, Japan).

The photo files were sent to AutoCAD 2010 software. Each photo was calibrated first by the true length of maxillary molar auxiliary tube with the "Align" order; then checked by measuring the length of lower molar auxiliary tube for accuracy.

Three lines were drawn tangential to the mesial aspects of hooks on molar tube (M) and canine bracket (C). Another line is drawn from the end of the wire from distal of the molar tube and perpendicular to the arch wire (E). All the lines had 3 mm distance from beneath the arch wire.

The distance between the M and C lines was measured in all photos. The Intraclass correlation coefficient was used to analyze the data with SPSS 17.

RESULTS

The mean and standard deviation values at the three time points is shown in Table. A high reliability coefficient of three items (.999, P-value: .009) was detected among the three photographs taken with half an hour intervals.

This method is a reliable and reproducible method for evaluation of tooth movement.

As seen in Figure 1, when B is the distance between C and M line and C is the distance between M and E lines; B' and C' are the distances when the teeth have been moved.

For measuring the amount of anchorage loss and canine retraction the following formulae can be used:

$$\text{Anchorage Loss} = C' - C$$

$$\text{Canine retraction} = B - B' - (C' - C)$$

DISCUSSION

In almost all studies, dental casts, their photo prints [1, 2, 4, 5, 7, 8, 11] and radiographs—such as: panoramic view, lateral cephalometry, intraoral periapical or submentovertex radiographs [1-4] are taken to evaluate tooth movement. The accuracy of current digital photographic assessment is assumed to be about 0.006 mm; whereas, the dimensional accuracy of laser surface scanned digital models has reported to be 0.05 mms [12]. In some other studies, the authors compared digital models with plaster ones [12, 13, 5]. Although the newly introduced technology of digital model has shown to be reliable, it does not seem to be economic for evaluation of tooth movement as no study is in this field.

In this investigation, we decided to introduce analysis of intraoral photographs with Auto-CAD software, which can be beneficial for the clinicians in the following fields:

(A) having patient records instantly accessible in contrast to retrieving the plaster models from the storage; (B) a reliable, accurate and easy measurement; (C) their comfortable storage, not occupying space; and (D) be easily shared for research purposes or consultation with a restorative dentist, periodontist or another orthodontist; (E) no need for arch wire removal, thus, it saves time and prevents distortion of wire. All the previously used techniques have some advantages and significant disadvantages. The advantages of cast analysis include the accessibility and simplicity of the measurement of these records. But there is a need to remove the archwire at each visit [14], taking an impression which is annoying for the patients and elaborate pouring and cast fabrication. In addition, the probability of tooth movement, even in the limit of PDL, can be expected during taking the impression.

Although lateral cephalograms are advantageous for evaluation of the relationship of the teeth to the underlying skeletal tissue [3], some disadvantages have been reported. One of them is the effective radiation dose; which is 2.4-6.2 μSv for a cephalometric radiograph [15]. It is well known that X-ray can disrupt cell mitosis and cause DNA damage. This can lead to somatic or genetic mutations [13].

The two other disadvantages include: irradiation cost and magnification of different anatomic sites. All these issues encouraged us not to use this technique. Given that the patient and film position as well as the type of cephalometric unit are the same, the magnification of a single lateral cephalogram is 0-24% in different areas [16]. On the other hand, the most significant error in cephalometry is wrong localization of the landmarks.

Table 1. Table of variables

Variables	Mean	Standard deviation	Cases
T1	21.4276	1.0918	72.0
T2	21.4232	1.0917	72.0
T3	21.4213	1.0951	72.0

In using panoramic radiography, it is particularly important to center the object directly within the focal trough to prevent differences in size, form and location of structures. The most susceptible areas to false interpretation of root alignment are the areas between the canine and premolar teeth of upper and lower jaws, which we need more for canine retraction[17].

The disadvantages of these techniques may force the clinician to record the events just at the first visit and the end of space closure [18, 14] missing the fluctuations in tooth movement during retraction.

Analyzing the photographs with the AutoCAD software enables the clinicians to calibrate the photo and achieve almost the true measures. Thus, magnification is not an issue. The distances and degrees can be recorded as accurate as wished. In this study, we adjusted the accuracy on 0.01 mm, which is adequate for our measures. Higher accuracy does not affect the clinical judgment. We selected the line with higher reproducibility. For example, we did not use the C line at mesial or distal sides of the bracket because they were masked either by the elastomeric ring or the ligature wire. The inner aspect of the distal wing of the bracket was the most suitable line.

Two other lines were drawn. M line was drawn just at the mesial aspect of the upper third of the molar hook, which is attached to the tube. The E line at the end of the archwire was drawn perpendicular to the archwire. All the lines were 3 mm long. All the measurements were done by one clinician.

When measuring the distances, the end point tab in the AutoCAD software was activated to accurately detect the end of each line.

It is an efficient way especially for research or teaching purposes to accurately follow tooth movement during retraction. The most significant advantage of intraoral photographs is saving time. In this study, we did not need to remove the arch wire, only minimal adjustments whenever required.

Although it does not show the accurate position of roots, it is efficient in studying tooth response to orthodontic forces especially at shorter intervals.

CONCLUSION

Intraoral photographs analyzed with AutoCAD software are efficient and economic for evaluation of tooth movement. Based on the current study, this measurement is reliable for evaluation of tooth movement during treatment. Further studies are needed to standardize the photographs.

ACKNOWLEDGEMENTS

Current study was accepted by Vice-Chancellor of Research of Shahid Sadoughi University of Medical Sciences.

REFERENCES

- 1- Shpack N, Davidovitch M, Sarne O, Panayi N, Vardimon AD. Duration and anchorage management of canine retraction with bodily versus tipping mechanics. *Angle Orthod.* 2008 Jan;78(1):95-100. doi: 10.2319/011707-24.1.
- 2- Darendeliler MA, Darendeliler H, Uner O. The drum spring (DS) retractor: constant and continuous force for canine retraction. *Eur J Orthod.* 1997 Apr;19(2):115-30.
- 3- Sueri MY, Turk T. Effectiveness of Lacement Ligatures on Maxillary Canine Retraction. *Angle Orthod.* 2006 Nov;76(6):1010-4.
- 4- Häsler R, Schmid G, Ingervall B, Gebauer U. A clinical comparison of the rate of maxillary canine retraction into healed and recent extraction sites—a pilot study. *Eur J Orthod.* 1997 Dec;19(6):711-9.
- 5- Santoro M, Galkin S, Teredesai M, Nicolay OF, Cangialosi TJ. Comparison of measurements made on digital and plaster models. *Am J Orthod Dentofacial Orthop.* 2003 Jul;124(1):101-5.
- 6- Hoggan BR, Sadowsky C. The use of palatal rugae for the assessment of anteroposterior tooth movements. *Am J*

- Orthod Dentofacial Orthop. 2001 May;119(5):482-8.
- 7- Gulati S, Kharbanda OP, Parkash H. Dental and skeletal changes after intraoral molar distalization with sectional jig assembly. Am J Orthod Dentofacial Orthop. 1998 Sep;114(3):319-27.
- 8- Rajcich MM, Sadowsky C. Efficacy of intraarch mechanics using differential moments for achieving anchorage control in extraction cases. Am J Orthod Dentofacial Orthop. 1997 Oct;112(4):441-8.
- 9- Naidu D, Freer TJ. Validity, reliability, and reproducibility of the iOC intraoral scanner: a comparison of tooth widths and Bolton ratios. Am J Orthod Dentofacial Orthop. 2013 Aug;144(2):304-10.
- 10- Cuperus AM, Harms MC, Rangel FA, Bronkhorst EM, Schols JG, Breuning KH. Dental models made with an intraoral scanner: a validation study. Am J Orthod Dentofacial Orthop. 2012 Sep;142(3):308-13. doi: 10.1016/j.ajodo.2012.03.031.
- 11- Keles A, Sayinsu K. A new approach in maxillary molar distalization: intraoral bodily molar distalizer. Am J Orthod Dentofacial Orthop. 2000 Jan;117(1):39-48.
- 12- Stevens DR, Flores-Mir C, Nebbe B, Raboud DW, Heo G, Major PW. Validity, reliability, and reproducibility of plaster vs digital study models: comparison of peer assessment rating and Bolton analysis and their constituent measurements. Am J Orthod Dentofacial Orthop. 2006 Jun;129(6):794-803.
- 13- Leifert MF, Leifert MM, Efstratiadis SS, Cangialosi TJ. Comparison of space analysis evaluations with digital models and plaster dental casts. Am J Orthod Dentofacial Orthop. 2009 Jul;136(1):16.e1-4; discussion 16.
- 14- Dixon V, Read MJ, O'Brien KD, Worthington HV, Mandall NA. A randomized clinical trial to compare three methods of orthodontic space closure. J Orthod. 2002 Mar;29(1):31-6.
- 15- Brooks SL. CBCT Dosimetry: Orthodontic Considerations. Seminars in Orthodontics. 2009;15(1):14-8.
- 16- Jacobson A JR. Radiographic Cephalometry from basic to 3-D imaging. St.Louis: Quintessence publishing; Co Inc; 2006. pp. 233-47.
- 17- Mozzo P, Procacci C, Tacconi A, Martini PT, Andreis IA. A new volumetric CT machine for dental imaging based on the cone-beam technique: preliminary results. Eur Radiol. 1998;8(9):1558-64.
- 18- Nightingale C, Jones SP. A clinical investigation of force delivery systems for orthodontic space closure. J Orthod. 2003 Sep;30(3):229-36.