

A rare case of prosthetic aortic valve endocarditis complicated with multiple fistula to peri aortic structure

Feridoun Sabzi¹, Reza Faraji²

Received: 7 October 2013

Accepted: 14 June 2014

Published: 10 December 2014

Abstract

Multiple aorto-cardiac cavity communications is very rare but important complication of prosthetic aortic valve endocarditis. The case below illustrates multiple aorto-cardiac cavity fistula formation following prosthetic aortic valve endocarditis presented with slowly progressive symptoms of heart failure. A brief review of surgical reconstruction and the existing literature are presented, including emphasis on pre and intra operative echocardiographic diagnosis and treatment.

Keywords: Aorto-cardiac, Aortic valve endocarditis, Fistula.

Cite this article as: Sabzi F, Faraji R. A rare case of prosthetic aortic valve endocarditis complicated with multiple fistula to peri aortic structure. *Med J Islam Repub Iran* 2014 (10 December). Vol. 28:146.

Introduction

According to Archer (1), it has been reported that aorto-cavitary fistula occurs from all three aortic valve sinuses to all four cardiac chambers. Prosthetic valve endocarditis is considered to be 15% of all infectious endocarditis in developed countries, more frequently during the first three months after surgery (2). Approximately half of patients with prosthetic valve endocarditis present with periannular invasion and cavity and abscess formation. The aortic valve involvements with early symptoms are related with a higher power of aggressive prosthetic endocarditis invasion (3). We present the case of a patient affected with early aortic prosthetic valve endocarditis by *S. aureus* with a high aggressive and proliferating course, accompanied by fistula to right ventricle, left atrium and pulmonary trunk, and severe aortic regurgitation with aortic wall necrosis detected at the time of surgery. However multiple aortic-cardiac cavity fistulas with necrosis of aortic and pulmonary walls are extremely

rare. We present a patient with early aortic prosthetic endocarditis secondary to *Staphylococcus aureus* with aggressive progression, which was refractory to medical treatment and ended in multiple aorto cavity fistulas, managed with surgical intervention.

Case report

A 36 year old woman with history of aortic valve replacement (AVR) referred to our center with progressive worsening fatigue, dyspnea and fever. Cardiac auscultation revealed a 4/6 diastolic murmur and pulmonary auscultation revealed bilateral crackles up to middle field. Also noted was bilateral malleolar edema. Blood test revealed leukocytosis and anemia and the biochemistry showed a creatinine of 3.5 mg/dL. Chest radiography revealed bilateral parenchyma infiltrates. Electrocardiogram showed a sinus rhythm, left anterior hemi block blockage, and signs of left and right ventricular hypertrophy. Suspecting endocarditis, blood culture and a transtho-

1. Department of Cardiovascular Surgery, Imam Ali Heart Center, Kermanshah University of Medical Sciences, Kermanshah, Iran.

2. (Corresponding author) Yazd Cardiovascular Research Centre, Shahid Sadoughi University of Medical Sciences, Yazd, Iran.
r.faraji61@gmail.com

raic echocardiogram were performed, which revealed good left and right ventricular function with concentric hypertrophy, slight dilatation, with a perivalvular abscess and a severe aortic insufficiency signal. The patient treated with voncomycin, rifampin and imipenem. A Transesophageal echocardiography (TEE) was subsequently performed which confirmed the previous findings and also identified the perianular abscess (Fig. 1) with small communication between the aorta and pulmonary artery

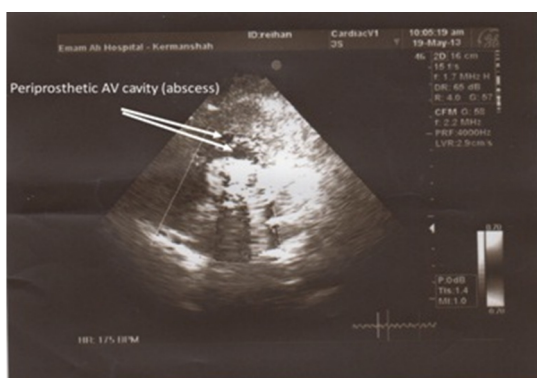


Fig. 1. Periannular abscess with perforation of aortic wall and right ventricular outflow tract (RVOT).

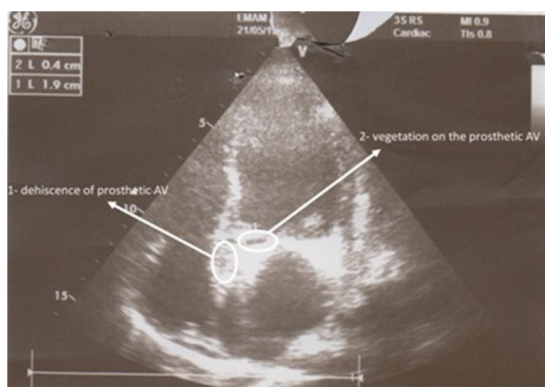


Fig. 2. Dehiscence of prosthetic aortic valve with vegetation.

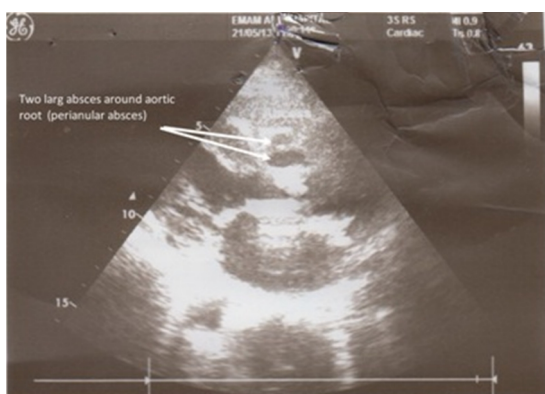

Fig. 3. Two large abscess cavities penetrated to RVOT and pulmonary artery.

(Fig. 2). The intraoperative TEE confirmed the diagnosis of severe prosthetic regurgitation (Fig. 3) and trans-valvar gradient (Fig. 4). Intra operative exploration after debridement of necrotic tissue and removal of cavity's vegetation demonstrated two other distinct perforations: first, through the posterior (superior) portion of left ventricular outflow tract (LVOT), at insertion of the anterior mitral leaflet to left atrium (Fig. 5) and second perforation was seen at the sinus of valsalva corresponding to the area of the right coronary cusp to main pulmonary trunk. On exploration, it was apparent that regurgitated blood flow moved around the infected aortic valve prosthesis into large abscess cavity (filled with vegetation) in aortic necrotic wall (Figs. 6,7) to 1- inter-ventricular septum to right ventricular outflow tract (RVOT), 2-to pulmonary artery, and 3-to LA. Vegetation ball in abscess cavity played as a one-way valve to blood flow and blocked blood flow movement as a left to right shunt in multiple fistulas to heart cavities. The mitral valve appeared to be intact, and no mitral regurgitation was seen. Lastly, evacuation of annular abscess cavity from vegetation and debridement of necrotic tissue adjacent to pulmonary trunk showed a small fistula to pulmonary trunk in which blood shunt was blocked by necrotic and vegetation tissue. The surgical procedure consisted of removal of the infected valve, resection of necrotic aortic wall between left and right coronary sinuses that extended to inter ventricular septum and to right ventricular out flow tract. Necrotic aortic wall reconstructed with fresh pericardial patch (Fig. 8) and aortic valve was replaced by a bi-leaflet mechanical valve. The aortic valve implanted on pericardial patch in necrotic right coronary sinus area. The fistula tracts to RVOT were obliterated by pericardial patch through RVOT approach. Fistula tract to left atrium was obliterated by sutures taken from the annulus of the anterior mitral valve leaflet exiting through the aortic side of the aortic annulus. Pulmonary trunk perforation was closed by small pericardial patch repair.

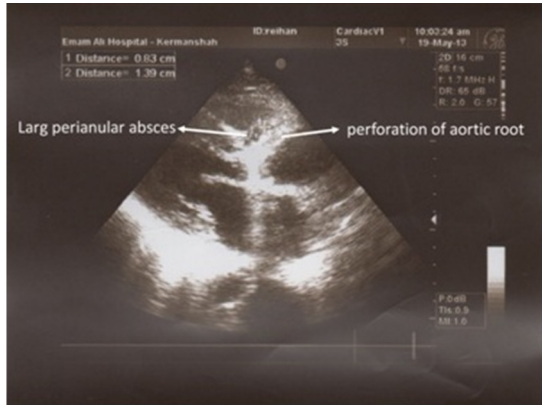

Figure 4. Necrosis of aortic wall in right coronary sinus due to large abscess cavity. Surgical debridement revealed fistula formation to main pulmonary artery and right ventricle.

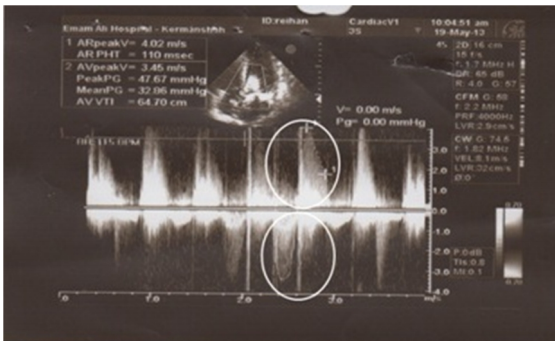


Figure 5. Echocardiography revealed increase in gradient of prosthetic valve by large vegetation.

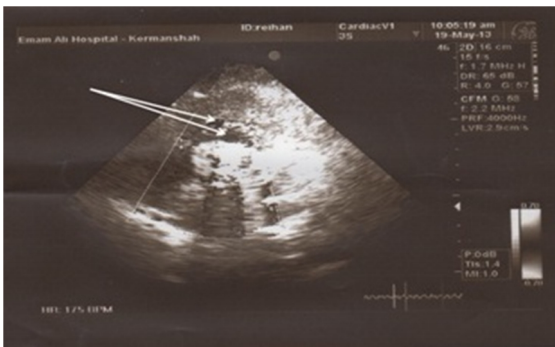


Figure 6. Large periprosthetic aortic valve abscess.

She was extubated within 24 hours. She subsequently had a prolonged ICU stay requiring reintubation on 4th postoperative day, because of reduced consciences and tachypnea. Repeat trans-thoracic echocardiograms confirmed clinical signs of a good repair with no vegetation or dehiscence of prosthetic valve. Repeated cultures were negative. The patient recovered well after 10 days and was discharged on the 30th postoperative day.

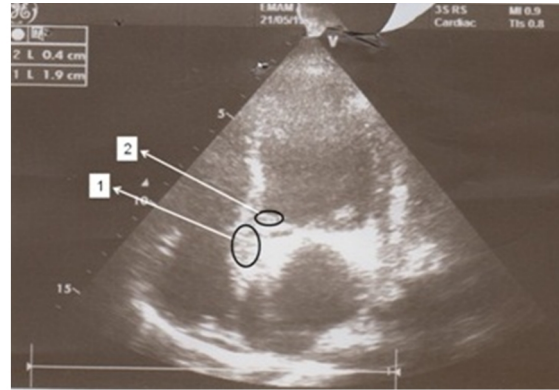


Figure 7. Dehiscence of prosthetic valve.

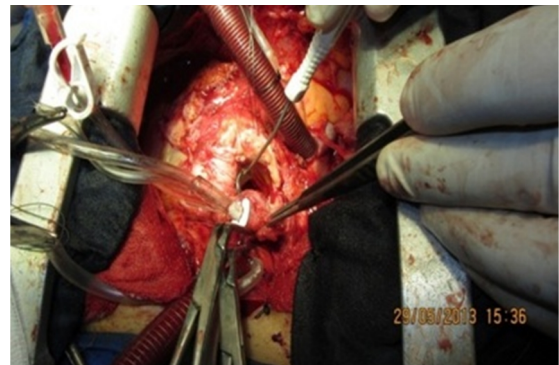


Figure 8. Intraoperative repair of necrotic right and left aortic coronary sinus wall with fresh pericardial patch.

Discussion

Middlemost stated (4) that endocarditis after prosthetic valve implantation occurs in 2%–4% of patients. Occasionally, as in our patient, aortic prosthetic valve abscesses involving the LVOT can lead to fistula formation into the right atrium, right ventricle and pulmonary artery. In the case presented, a periannular aortic valve abscess also had perforated into the left atrium, producing a systolic jet on color flow Doppler that was misinterpreted as mild mitral regurgitation on preoperative TTE. Intraoperative exploration established the correct diagnosis of aorto-left atrial fistula with a competent mitral valve (5). Multiple aorto-cavitary fistulas are seen infrequently, and limited cases of this fistula have been reported after aortic valve endocarditis. Crawford found (6) that presentation of aorta-cavitary fistulas is diverse in the etiology, size and acute or chronic nature of the fistula. The decision for the therapy is made depending on the size and clinical characteristics of the patient. Hemolytic

anemia, pulmonary hypertension, and right and/or left heart failure are the indications for treatment of the fistula. Aorta-RV fistulas and other paravalvular leakages are, conventionally, treated by open heart surgery. Experiences are limited for surgical treatment due to the infrequency of the disease (7). Percutaneous transcatheter is a novel choice for therapy but experiences are also limited like the surgical choice. Apparently, the coexistent complications with aorto-cavity fistula in the setting of aortic endocarditis such as presence of annular abscess, extension to the upper inter-ventricular septum or the subaortic area and pseudo aneurysm formation are best seen by TEE (8-10).

Conclusion

Periaortic valve abscess formation with paravalvular leakage and multiple fistulas is an important, serious complication of mechanical valve replacement and require a high index of suspicion for early diagnosis.

References

1. Arnett EN, Roberts WC. Valve ring abscess in active infective endocarditis; frequency, location and clues to clinical diagnosis from study of 95 necropsy patients. *Circulation* 1976 Jul; 54(1):140-5.
2. Archer TP, Mabee SW, Baker PB, Orsinelli DA, Leier CV. Aorto-left atrial fistula: A reversible

cause of acute refractory heart failure. *CHEST* 1997 Mar; 111(31):828-31.

3. Anguera I, Quaglio G, Miro JM, Pare C, Azqueta M, Marco F, et al . Aorticardiac fistulae complicating infective endocarditis. *Am J Cardiol* 2001 Mar; 87:28-26.

4. Middlemost S, Wisenbaugh T, Meyerowitz C, Teeger S , Essop R , Skoularigis J, et al. A case for early surgery in native left-sided endocarditis complicated by heart failure: results in 203 patients. *J Am Coll Cardiol* 1991 Sep;18 (3):667-663.

5. Choussat R, Thomas D, Isnard R, Michel PL, Iung B, Hanania G, et al. Perivalvular abscesses associated with endocarditis; clinical features and prognostic factors of overall survival in a series of 233 cases. *Eur Heart J* 1999 Feb; 20 (3):232-41.

6. Crawford MH, Durack DT. Clinical presentation of infective endo-carditis. *Cardiol Clin* 2003 May; 21 (2):159-66.

7. Dussaillant GR, Romero L, Ramirez A, et al. Successful percutaneous closure of paraprosthetic aorto-right ventricular leak using the Amplatzer duct occluder. *Catheter Cardiovasc Interv* 2006 Jun; 67 (6): 976-80.

8. Shapira Y, Vaturi M, Weisenberg DE, Raanani E, Sahar G, Snir E, et al. Impact of intraoperative transesophageal echocardiography in patients undergoing valve replacement. *Ann Thorac Surg* 2004 Aug; 78 (2):583-579.

9. Samuels LE, Kaufman MS, Rodriguez-Vega J, Morris RJ, Brockman SK. Diagnosis and management of traumatic aorto-right ventricular fistulas. *Ann Thorac Surg* 1998 Jan; 65 (1):288-92.

10. Phillips SA, Thompson A, Abu-Halimah A, Crenshaw MH, Zhao DX, Pretorius M. Percutaneous closure of aortic prosthetic paravalvular regurgitation with two amplatzer septal occluders. *Anesth Analg* 2009 Feb; 108 (2):437-8.