

Chronic Diarrhea Due to Duodenal Candidiasis in a Patient With a History of Kidney Transplantation

Nader Nouri-Majalan,¹ Sarasadat Moghaddasi,¹
 Mohammad Davud Qane,¹ Farzane Shefaie,¹
 Roghayyeh Masoumi Deshiri,¹ Mohammad Kassem Amirbaigy,²
 Mahmoud Baghbanian²

¹Division of Nephrology,
 Department of Internal
 Medicine, Shahid Sadoughi
 University of Medical Sciences,
 Yazd, Iran

²Division of Gastroenterology,
 Department of Internal
 Medicine, Shahid Sadoughi
 University of Medical Sciences,
 Yazd, Iran

Keywords. kidney
 transplantation, gastroenteritis,
 candidiasis

Candida infection in the small intestine is uncommon. We report an unusual case of duodenal candidiasis that presented as chronic diarrhea in a patient who had previously undergone kidney transplantation. A 60-year-old man presented with profuse watery diarrhea that had lasted 6 months 13 years after kidney transplantation. Upper gastrointestinal endoscopy results indicated candidiasis within the esophagus and duodenum. Biopsy results revealed active duodenitis with hyphal and yeast forms of *Candida* overlying the duodenal epithelium in periodic acid Schiff staining. The patient was successfully treated with fluconazole. After 6 months of follow-up, the patient had no complaint of diarrhea. Duodenal candidiasis may be the result of chronic diarrhea in patients with a history of kidney transplantation.

IJKD 2014;8:489-91
www.ijkd.org

INTRODUCTION

In humans, *Candida* is considered a normal flora within the gastrointestinal tract; however, *Candida* species may grow abnormally and may result in mucosal plaques on the oropharynx or esophagus in healthy or immunocompromised patients.^{1,2} *Candida* infection within the small intestine is uncommon, although a few cases of *Candida*-associated duodenal plaques and ulceration have been described.^{3,4} Duodenal candidiasis-associated diarrhea is very rare in cases of organ transplantation.⁵ Here, we report a case of chronic diarrhea due to duodenal candidiasis in a patient with a history of kidney transplantation.

CASE REPORT

A 60-year-old man with a history of chronic hypertension-induced end-stage renal disease who had undergone kidney transplantation 13 years earlier was admitted because of diarrhea that had lasted for 6 months. The watery diarrhea was of a

large volume and did not contain blood, mucus, or fat. The diarrhea was not controlled by fasting or changes in the patient's nutritional regimen. The patient had no history of nausea, vomiting, abdominal pain, tenesmus, or fever. Since the diarrhea initiation, he had lost approximately 25 kg; in addition, he had lost his appetite. The diarrhea persisted even after the patient discontinued the treatment with mycophenolate mofetil.

On admission, he was under the immunosuppressive drug therapy involving prednisolone, 5 mg/d, and cyclosporine, 100 mg/d. The patient was also taking pantoprazole, 20 mg/d. Physical examination revealed bitemporal atrophy and pale conjunctivae. Laboratory test results included the following: serum bicarbonate level, 5 mEq/L; creatinine level, 5.6 mg/dL; leukocyte count, $4.3 \times 10^9/L$; hemoglobin level, 10.6 g/dL; platelet count, $192 \times 10^9/L$; erythrocyte sedimentation rate, 10 mm/h; and C-reactive protein, negative. The patient's serum was negative for hepatitis

B surface antigens, hepatitis C virus antibodies, human immunodeficiency virus antibodies, and cytomegalovirus immunoglobulin M antibodies. No leukocytes, erythrocytes, or parasites were observed in his stool sample.

Upper gastrointestinal endoscopy showed multiple patchy white plaques on the esophageal and duodenal mucosa. No ulcers or other abnormalities were noted (Figure 1). Hematoxylin-eosin and periodic acid Schiff staining of the duodenal biopsy specimens indicated hyphal and yeast forms of *Candida* overlying the duodenal epithelium as well as moderate mixed inflammatory reaction and diffuse infiltration of polymorph nuclear and lymphoplasmacyte cells in lamina propria compatible with active duodenitis (Figures 2 and 3).

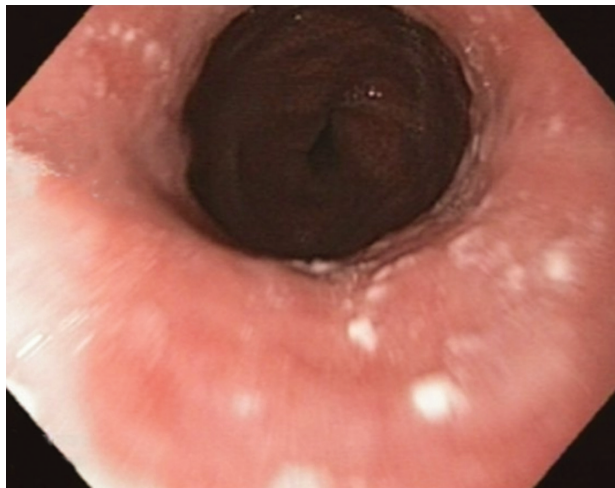


Figure 1. Multiple patchy white plaques on the esophageal and duodenal mucosa on upper gastrointestinal endoscopy.

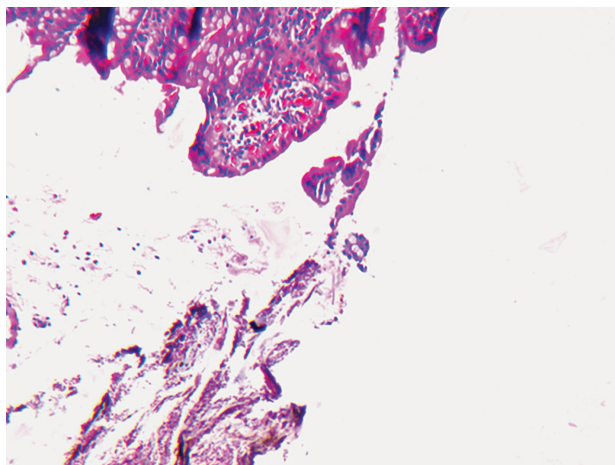


Figure 2. Hyphal and yeast forms of *Candida* overlying the duodenal epithelium as well as active duodenitis (hematoxylin-eosin, × 10).

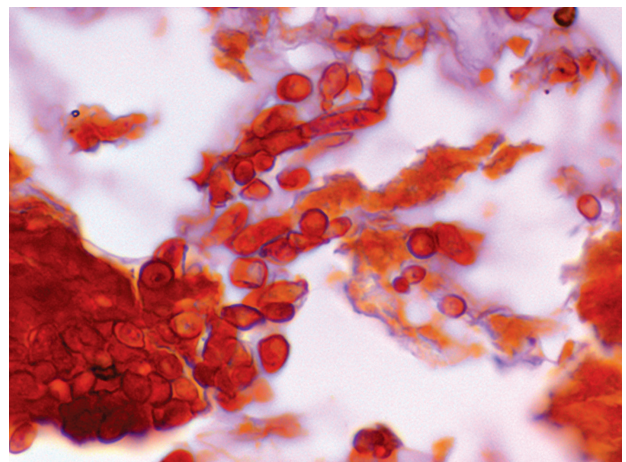


Figure 3. Hyphal and yeast forms of *Candida* (periodic acid Schiff, ×100).

Small bowel transition study and colonoscopy findings were normal.

The patient was given fluconazole, 200 mg/d. Subsequently after 2 days, he experienced relief from diarrhea. At discharge, the patient's serum bicarbonate level was 10.3 mEq/L, and his serum creatinine level was 3 mg/dL. During the 6-month follow-up, serum creatinine level was around 3 mg/dL and during this time, the patient had no complaint of diarrhea.

DISCUSSION

Our diagnosis of duodenal candidiasis-associated diarrhea was based on the clinicopathological evidence and the patient's response to fluconazole. Mycophenolate mofetil may be associated with gastrointestinal adverse effects, including diarrhea; however, despite discontinuation of this medication, the patient continued to experience diarrhea.

Possible causes of diarrhea in kidney transplant patients consist of infection and medications, especially mycophenolate mofetil.⁶ Some infectious causes are *Clostridium difficile*, *Campylobacter jejuni*, cytomegalovirus, *Microsporidia*, *Strongyloides rcoralis*, and *Cryptosporidium parvum*.⁷ Duodenal candidiasis is uncommon. Rajablou and coworkers³ reported a patient with chronic lymphocytic leukemia who had multiple ulcerous masses in the stomach and duodenum. A duodenal ulcer due to candidiasis was also described in a patient with immunoglobulin A deficiency and a T-cell defect.⁸ In the literature, we found only 1 case of a duodenal ulcer and jejunal candidiasis in a patient who had undergone kidney transplantation.⁵ In contrast to this study,

our patient presented with diarrhea only. Diarrhea due to duodenal candidiasis is very rare.⁹ Gupta and colleagues¹⁰ described 10 patients hospitalized because of severe diarrhea associated with abnormal *Candida* growth in the intestine.

Our patient had a history of taking pantoprazole. Acid-reducing therapy is known to result in *Candida* overgrowth.¹¹ Therefore, in our patient, both immunosuppressive therapy and the long-term use of the proton pump inhibitor may have caused duodenal candidiasis. In summary, duodenal candidiasis-associated diarrhea may occur in patients with a history of kidney transplantation.

CONFLICT OF INTEREST

None declared.

REFERENCES

1. Wilcox CM, Schwartz DA. Endoscopic-pathologic correlates of *Candida* esophagitis in acquired immunodeficiency syndrome. *Dig Dis Sci*. 1996;41:1337-45.
2. Kods BE, Wickremesinghe C, Kozinn PJ, et al. *Candida* esophagitis: a prospective study of 27 cases. *Gastroenterology*. 1976;71:715-9.
3. Rajablou M, Ganz RA, Batts KP. *Candida* infection presenting as multiple ulcerated masses. *Gastrointest Endosc*. 2007;65:164-6.
4. Prescott RJ, Harris M, Banerjee SS. Fungal infections of the small and large intestine. *Clin Pathol*. 1992;45:806-11.
5. Joshi SN, Garvin PJ, Sunwoo YC. Candidiasis of the duodenum and jejunum. *Gastroenterology*. 1981; 80:829-33.
6. Maes BD, Dalle I, Geboes K, et al. Erosive enterocolitis in mycophenolate mofetil-treated renal-transplant recipients with persistent afebrile diarrhea. *Transplantation*. 2003;75: 665-72.
7. Davies NM, Grinyó J, Heading R, et al. Gastrointestinal side effects of mycophenolic acid in renal transplant patients. *Nephrol Dial Transplant*. 2007;22:2440-8.
8. Singh S, Kochhar R, Dutta U. Severe duodenal candidiasis in a patient with IgA deficiency and T cell defects. *Indian J Gastroenterol*. 1990;9:95-6.
9. Friedman M, Ramsay DB, Borum ML. An unusual case report of small bowel *Candida* overgrowth as a cause of diarrhea and review of the literature. *Dig Dis Sci*. 2007;52:679-80.
10. Gupta TP, Ehrinpreis MN. *Candida*-associated diarrhea in hospitalized patients. *Gastroenterology*. 1990;98:780-5.
11. Goenka MK, Kochhar R, Chakrabarti A, et al. *Candida* overgrowth after treatment of duodenal ulcer. A comparison of cimetidine, famotidine, and omeprazole. *J Clin Gastroenterol*. 1996;23:7-10.

Correspondence to:

Nader Nouri Majalan, MD

Department of Nephrology, Sadoughi Medical University, Yazd, Iran

E-mail: dr_nori_majalan@yahoo.com

Received June 2013

Revised February 2014

Accepted February 2014