

Endovascular Treatment of Post-Traumatic Pseudoaneurysms of Ulnar and Radial Artery

Hossein Nough, Mostafa Bagherinasab, Mahmood Emami, Mohammadtaghi Sarebanhassanabadi, and Leila Hadiani

Yazd Cardiovascular Research Center, Shahid Sadoughi University of Medical Sciences, Yazd, Iran

Received: 11 May 2013; Accepted: 29 Jan. 2014

Abstract- Aneurysm can develop in all arteries of the human body. Pseudoaneurysm induced by trauma is known as a rare condition in peripheral arteries. This complication is known as late sequelae of trauma. The incidence of pseudoaneurysm in upper extremities artery is less than lower extremities. Atherosclerotic aneurysms are often seen in large arteries and by aging, but pseudoaneurysm can be seen in penetrating or blunt trauma in patients of every age or every location. Delayed treatment of pseudoaneurysm leads to bleeding, venous edema at the extremities and compression on the adjacent nerve as a result of pseudoaneurysm enlargement. Early diagnosis of pseudoaneurysm is very important, because this complication can induce disabilities such as upper extremities and finger loss. Peripheral arteries pseudoaneurysm in distal locations especially in brachial artery and forearm can cause a thrombotic complication in hands and fingers.

© 2014 Tehran University of Medical Sciences. All rights reserved.

Acta Medica Iranica, 2014;52(11):865-867.

Keywords: Endovascular treatment; Traumatic pseudoaneurysm; Ulnar artery; Radial artery

Introduction

Aneurysm can develop in all arteries of the human body (1). Pseudoaneurysm induced by trauma is known as a rare condition in peripheral arteries. This complication is known as late sequelae of trauma. The incidence of pseudoaneurysm in upper extremities artery is less than lower extremities (2). Atherosclerotic aneurysms are often seen in large arteries and by aging, but pseudoaneurysm can be seen in penetrating or blunt trauma in patients of every age or every location (3,4). Delayed treatment of pseudoaneurysm leads to bleeding, venous edema at the extremities and compression on the adjacent nerve as a result of pseudoaneurysm enlargement (5). Early diagnosis of pseudoaneurysm is very important, because this complication can induce disabilities such as upper extremities and finger loss. Peripheral arteries pseudoaneurysm in distal locations especially in brachial artery and forearm can cause a thrombotic complication in hands and fingers (6).

Case Report

A 35-year-old man with right forearm gunshot

wound was admitted to Afshar Emergency Department. The patient was referred to an orthopedic surgeon for further evaluation and treatment. After orthopedic surgery and bone repair, he was transferred to the general ward. In the general ward blood, leakage was detected. So the patient was referred to the operation room again for surgical repair. Eight days after patient discharge, blood oozing was reported by the patient. He referred to cardio interventionist for vessel assessment. Cardiologist evaluation showed that the patient was hemodynamically stable and had no coagulopathy. Normal brachial, ulnar and radial pulses were recorded. Right finger capillary refilling was normal, and there was no sign of ischemia. Doppler ultrasound exam was done, but because of extensive injury, accurate finding was not obtained. No abnormal finding was achieved. Then the doctors decided to perform right upper extremities angiography. The patient underwent a transfemoral right brachial and forearm angiography, and the diagnosis of pseudoaneurysm and blood leakage on the proximal part of ulnar and radial arteries was confirmed (Figure 1). The decision to perform endovascular stent-graft was made by the interventional cardiologist in order to correct blood leakage of right

Corresponding Author: M. Bagherinasab

Yazd Cardiovascular Research Center, Shahid Sadoughi University of Medical Sciences, Yazd, Iran
Tel: +98 351 5231421, Fax: +98 351 5253335, E-mail address: bagherinasab.mostafa@gmail.com

Endovascular treatment of pseudoaneurysm

ulnar pseudoaneurysm. Following the diagnostic angiography, a 6FJR guiding catheter a .014 inch coronary floppy tipped guide wire was used to cross the injured segment of the arteries. A 12-mm coronary stent graft with diameter of 2.75-mm was chosen and it was advanced over the guide wire and placed across the false aneurysmatic segment of right ulnar artery under fluoroscopic road mapping guidance and deployed with 20 atmosphere pressure. After the procedure, angiogram revealed that there was no bleeding in the ulnar artery

(Figure 2). To prevent development and rupture of right radial artery, at the same time, a .014 inch coronary floppy tipped guide wire was used to cross the injured part of the artery. A 15-mm coronary stent graft with diameter of 3-mm with pressure of 22 atmospheres was inserted (Figure 3).

The patient follow-up for 6 months showed that radial and ulnar arteries were normal, and there was no sign of ischemia.

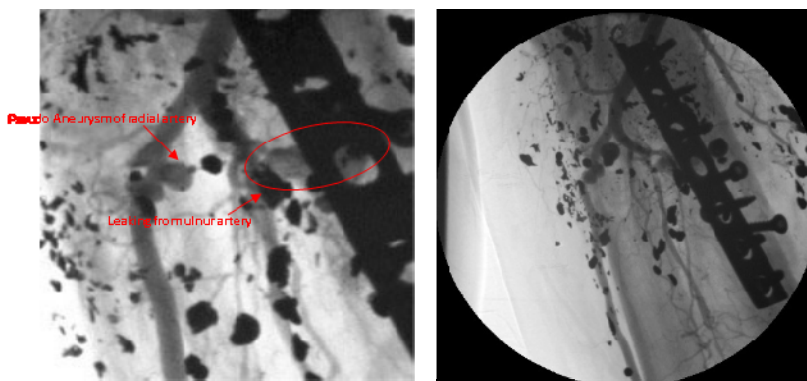


Figure 1. Pseudoaneurysms of radial artery and leakage in the ulnar artery




Figure 2. Stenting in ulnar artery

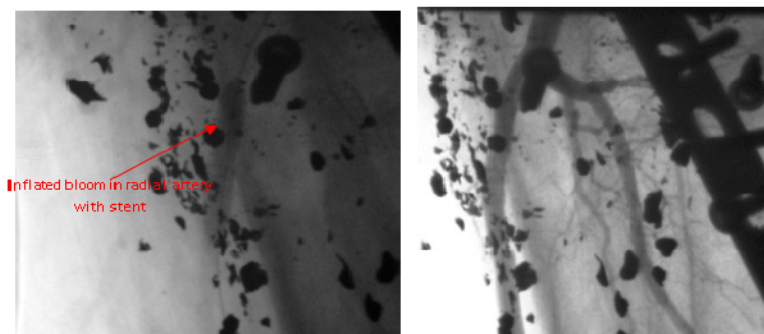


Figure 3. Inflated balloon in the radial artery and after stenting in the radial artery

Discussion

Pseudoaneurysm is known as a complication of penetrating trauma. If the only cause of aneurysm is trauma, it takes the form of a pseudoaneurysm. The most important pathogenesis of upper extremities pseudoaneurysms is infection, congenital arteries defects and trauma. (4,8). Pseudoaneurysm or false aneurysm results from arterial wall penetrating trauma. Pseudoaneurysms of ulnar and radial arteries are rare conditions. Distal segment of radial artery is superficial, so this part is considered as a vulnerable spot. Aneurysm of the ulnar artery occurs after penetrating wound, bone fracture and use of external fixator (8,9).

In pseudoaneurysm cases, Doppler ultrasonography and magnetic resonance imaging are considered as diagnostic devices, but the gold standard is selective upper extremities arteriography (10,11). In this case, Doppler ultrasonography evaluation was done for patient follow-up. Endovascular graft implantation is a new and minimally invasive and can be used for aneurysms and pseudoaneurysms of principal arterial system (12).

In this article, we presented a case of traumatic radial and ulnar pseudoaneurysm that had the feature of blood oozing in patient who had a history of penetrating trauma. After the diagnosis had been confirmed by Doppler ultrasound and angiography, the patient was treated with catheter-based stent-graft insertion via RT femoral artery approach.

References

1. Crawford ES, De Bakey ME, Cooley DA. Surgical considerations of peripheral arterial aneurysms; analysis of one hundred seven cases. *AMA Arch Surgery* 1959;78(2):226-38.
2. Wielenberg A, Borge MA, Demos TC, et al. Traumatic pseudoaneurysm of the brachial artery. *Orthopedics* 2000;23(12):1250,1322-4.
3. Johnston KW, Rutherford RB, Tilson MD, et al. Suggested standards for reporting on arterial aneurysms. Subcommittee on Reporting Standards for Arterial Aneurysms, Ad Hoc Committee on Reporting Standards, Society for Vascular Surgery and North American Chapter, International Society for Cardiovascular Surgery. *J Vasc Surg* 1991;13(3):452-8.
4. Yilmaz AT, Arslan M, Demirkilic U, et al. Missed arterial injuries in military patients. *Am J Surg* 1997;173(2):110-4.
5. Robbs JV, Naidoo KS. Nerve compression injuries due to traumatic false aneurysm. *Ann Surg* 1984;200(1):80-2.
6. Nugud OO, Hedges AR. Axillary artery pseudoaneurysm. *Int J Clin Pract* 2001;55(7):494.
7. Robbs JV, Naidoo KS. Nerve compression injuries due to traumatic false aneurysm. *Ann Surg* 1984;200(1):80-2.
8. Offer GJ, Sully L. Congenital aneurysm of the ulnar artery in the palm. *J Hand Surg Br* 1999;24(6):735-7.
9. Wang AA, Strauch RJ, Moore JA. Pseudo-aneurysm of the ulnar artery occurring after fracture of the distal radius and ulna: a case report. *J Hand Surg Am* 1998;23(5):933-7.
10. Haimovici H. Peripheral arterial aneurysms. In: Haimovici H, Ascer E, Hollier LH, et al, editors. *Haimovici's vascular surgery*. 4th ed. Cambridge (MA): Blackwell Science; 1996: p. 893-909.
11. Tetik O, Yetkin U, Yilik L, et al. Right axillary pseudoaneurysm causing permanent neurological damage at right upper limb: A case report. *Turk J Vasc Surg* 2002;2:102-4.
12. Cakir O, Balci AE, Eren S, et al. Traumatic arteriovenous fistulas. *Turk J Vasc Surg* 2001;1(1):28-31.