

Search for a cause of disseminated intravascular coagulopathy resulted in finding metastatic prostate cancer

Mohammad Forat Yazdi¹, Golnaz Malekzadeh²

¹Internal Medicine Department of Shahid Sadoughi University of Medical Sciences, Yazd, Iran

²Shahid Sadoughi University of Medical Sciences, Yazd, Iran

Article history

Submitted: Oct. 23, 2012

Accepted: March 23, 2013

Correspondence

Golnaz Malekzadeh

Shahid Sadoughi Hospital

Yazd, Iran

phone: +98 913 253 6332

golnaz_malek_zade@yahoo.com

Disseminated intravascular coagulopathy (DIC) is an acquired disease that occurs secondary to a variety of underlying conditions including solid tumors. Prostate cancer (PCa) is one of these tumors and DIC is the most prevalent coagulopathy related to PCa, but it is rarely reported as the first manifestation of it. This paper is a report of an 85-year-old man who presented with hematuria and vast ecchymoses. Thorough work-up resulted in finding metastatic PCa with DIC as presenting condition. Although DIC is a rare manifestation of metastatic prostate cancer, it should be considered when no other reason can be found to explain it.

Key Words: metastatic prostate cancer ◊ disseminated intravascular coagulopathy

INTRODUCTION

Disseminated intravascular coagulation (DIC) is a pathological activation of coagulation mechanisms. Normally, the body forms a blood clot in reaction to an injury. With DIC, the body overproduces fibrin which activates coagulation system. Microthrombi cause induce ischemia and depleting the body of clotting factors and platelets. Massive bleeding can occur due to the body's lack of clotting factor and platelets. Microthrombi can interfere with the blood supply to organs causing dysfunction and failure. DIC is life-threatening. Its prognosis, regardless of cause, is often poor and needs to be treated promptly [1, 2].

DIC is not itself a specific illness; rather, it is a complication or an effect of the progression of other illnesses. It is always secondary to an underlying disorder and is associated with a number of clinical conditions, generally involving activation of systemic inflammation. Such conditions include the following: recent episode of sepsis, anesthesia, surgery or trauma, reaction to blood transfusion, severe liver disease, delivery complications, leukemia, and solid cancers [3].

There are two types of DIC, acute and chronic. Acute DIC develops quickly (over hours or days) and must be treated immediately. The condition begins with excessive clot formation in the small blood vessels and quickly leads to serious bleeding. Chronic DIC develops slowly (over weeks or months). It lasts longer and usually is not recognized as quickly as acute DIC. Chronic DIC causes excessive blood clotting, but it usually does not lead to bleeding. Cancer is the most common cause of chronic DIC; gastric, pancreatic, and prostatic cancers are notorious [4].

Prostate cancer is one of the solid tumors that is the most common malignancy in men and is the second cause of death in men among neoplastic diseases [5]. Bone metastasis is very frequent in this cancer; up to 90% of advanced prostatic cancer has skeletal metastasis [6]. DIC secondary to prostate cancer is not that rare, but only several cases of the initial presentation have been reported [7–15].

In this paper we discuss an 85-year-old man who fulfilled the criteria for diagnosis of DIC. The consequent investigation as to the underlying disease resulted in the discovery of metastatic prostate cancer.

CASE PRESENTATION

An 85-year-old man was admitted to the accident and emergency ward with vast ecchymoses that first emerged in his left popliteal area 15 days prior and gradually progressed to the inguinal area. Both auxiliary and flank areas were also involved. He had a history of hematuria and bleeding from his lower lip, which could not be easily controlled. There was no history of melena, gastrointestinal bleeding, hemoptysis, or epistaxis. He also mentioned a significant weight loss and low appetite. His past medical history was remarkable for a two-year history of hypertension, which was under medical therapy with losartan, nitroglycerin, metolazone, Metoral, and amlodipine. He also had a history of unstable angina and transurethral resection of the prostate seven years ago.

At the time of admission his vital signs were stable. There was no remarkable point in his physical exam. Neither palpable peripheral lymph node nor hepatosplenomegaly was detected.

As the initial procedure, his blood was harvested for laboratory tests. The laboratory workup revealed low levels of hemoglobin, low platelet count in CBC, and low fibrinogen along with prolonged prothrombin time (PT) and partial thromboplastin time (PTT). International normalized ratio (INR) was significantly higher than its normal ranges (Table 1). To prove the presence of DIC, hematologic factors V, VII, and VIII

Table 1. Results of laboratory tests of the patient in emergency ward

Laboratory test	Patient's lab results	Normal range
WBC	6300/ μ L	3500–10000/ μ L
Hb	11.2 gr/dl	11.5–18.8 gr/dl
Plt	61000/ μ L	140000–400000/ μ L
PT	25 seconds	11–14 seconds
PTT	35 seconds	25–35 seconds
INR	4	1–1.25
Urea	96 mg/dl	10–50 mg/dl
Creatinine	1.5 mg/dl	0.4–1.5 mg/dl
Uric acid	8.2 mg/dl	4–7 mg/dl
AST	42 μ L	5–40 μ L
ALT	16 μ L	5–40 μ L
Alkaline phosphatase	9336 μ L	80–306 μ /L
Bilirubin (Total)	2.6 mg/dl	0.2–1.2 mg/dl
Bilirubin (Direct)	1.6 mg/dl	Up to 0.25 mg/dl
LDH	962 μ L	225–500 μ L
CPK	406 μ L	24–195 μ L
D-dimer	664.1 μ gr/ml	Less than 300 μ gr/ml
Fibrinogen	Less than 30 mg/dl	200–400 mg/dl
FBS	149 mg/dl	70–110 mg/dl
Anti-cardiolipin IgG	3.8 U/ml	More than 18 U/ml
Anti-cardiolipin IgM	1.7 U/ml	More than 18 U/ml
Anti-phospholipid IgG	7.2 U/ml	More than 18 U/ml
Anti-phospholipid IgM	3.3 U/ml	More than 18 U/ml

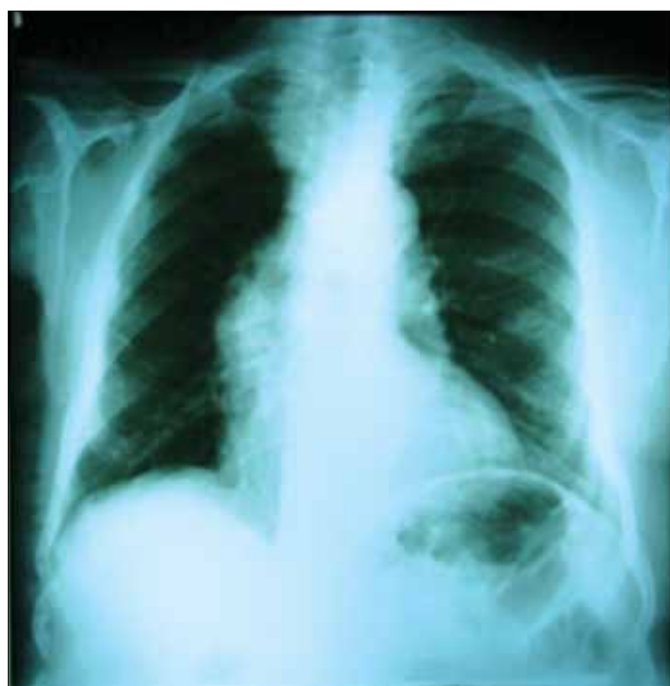

Figure 1. Opacities in chest X-Ray suggesting lung metastasis.

were checked, which were found to be below their normal ranges.

As signs and results of test were suggesting DIC he was subjected to supportive therapy. The patient received vitamin K, one unit of packed red cells, and two units of fresh frozen plasma. His profession as a butcher prompted suspicion of Crimean–Congo hemorrhagic fever. The patient consequently was hospitalized in isolation, blood samples were sent for serology and PCR, and he underwent treatment with Ribavirin, but he was unresponsive to therapy. During the days of hospitalization, the level of Hb went from 11.2 to 8.1 gr/dl while PT and PTT became immeasurable, so he was treated with one unit of fresh frozen plasma twice a day. As the results of PCR and serology were negative, further investigations included direct and indirect Coombs tests for anti-cardiolipin and anti-phospholipid IgGs and IgMs, but were all found to be negative.

In order to rule out the possibility of malignancies such as gastric, pancreatic and prostatic cancers that could

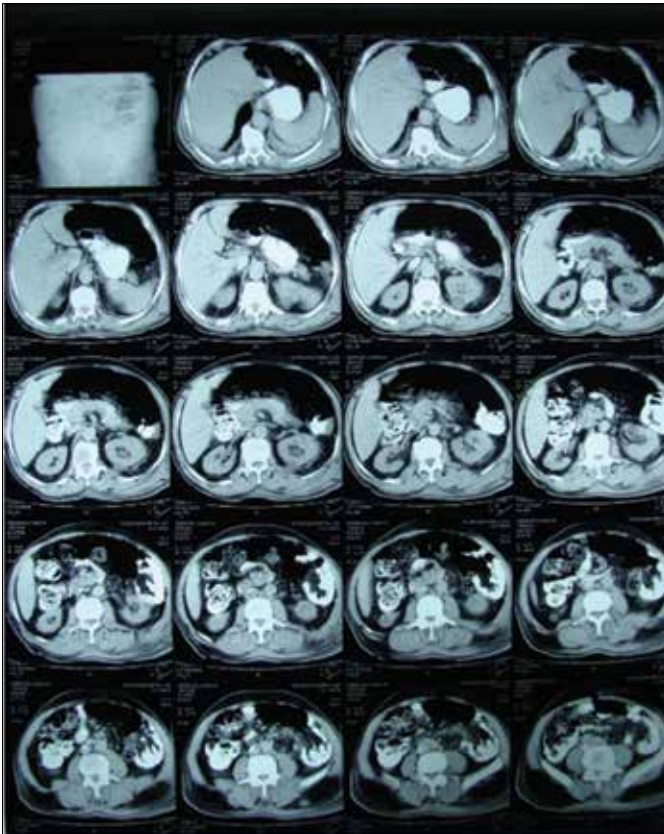


Figure 2. Abdominopelvic CT scan with oral and intravenous contrast.

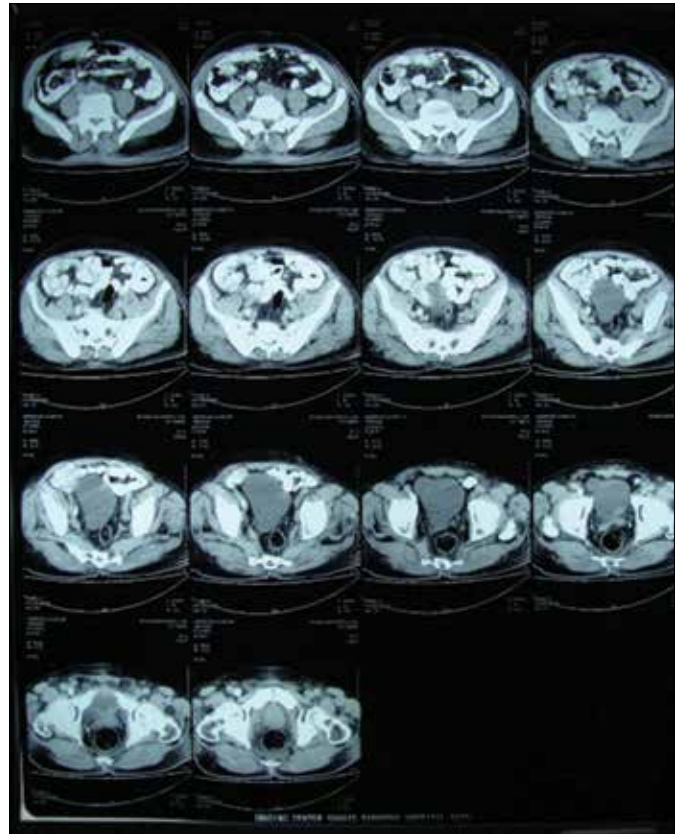


Figure 3. Abdominopelvic CT scan with oral and intravenous contrast.

have led to DIC [16], abdominopelvic sonography and chest x-rays were also performed. The chest x-ray (Figure 1) revealed some opacities so chest and abdominopelvic computed tomography scan with oral and intravenous contrast was performed (Figs. 2, 3 and 4). Neither para-aortic adenopathy nor abnormal collection nor mass were reported, but several nodules with speculated and irregular margins was seen in the lungs, the largest of which was located in the apex of left lung and was approx. 2 cm in largest dimension. Mild bilateral pleural effusion with the dominance to the left side also was reported. These findings were suggestive for metastasis. Endoscopy was performed to find a gastric origin, but only a small hiatal hernia was observed. To rule out the pancreatic and prostatic origin, abdominopelvic sonography was performed. The report indicated kidneys, bladder, spleen, and liver to be normal, but an ill-defined area with an estimated volume of 10 ml was seen in the prostate. It was hypoechoic and contained small hyperechoic areas that suggested calcifications. Consequently, the results of the ultrasonography directed all our attention to the prostate gland.

According to the findings from imaging, prostate specific antigen (PSA) was measured and found to be 1,542 ng/ml. A whole body bone scan revealed

a number of metastatic areas in bone that were the foci that lead to the DIC.

Upon confirming the diagnosis the patient underwent treatment. As orchiectomy was not possible, hormonal ablation followed by chemotherapy with Taxotere 100 mg every 21 days was prescribed to him. He was then discharged with normal PT and PTT and no source of bleeding after the first course of chemotherapy.

DISCUSSION

In this paper we reported an 85-year-old man with vast ecchymoses and bleeding. His laboratory work-up consisted of decreased platelet count, prolonged PT and PTT, decreased level of fibrinogen, increased level of LDH, and D-dimer, which confirmed the presence of DIC. The diagnostic procedures to find the underlying cause of DIC ended up in the discovery of metastatic prostate cancer.

Bone is the most common site of metastasis in prostate cancer and it is responsible for inducing DIC even more than gastric and pancreatic cancer [4]. The incidence rate of DIC is 13–30% in metastatic prostate cancer, [16] but it is infrequent as the first manifestation [1, 2, 7]. The first symptom in our pa-

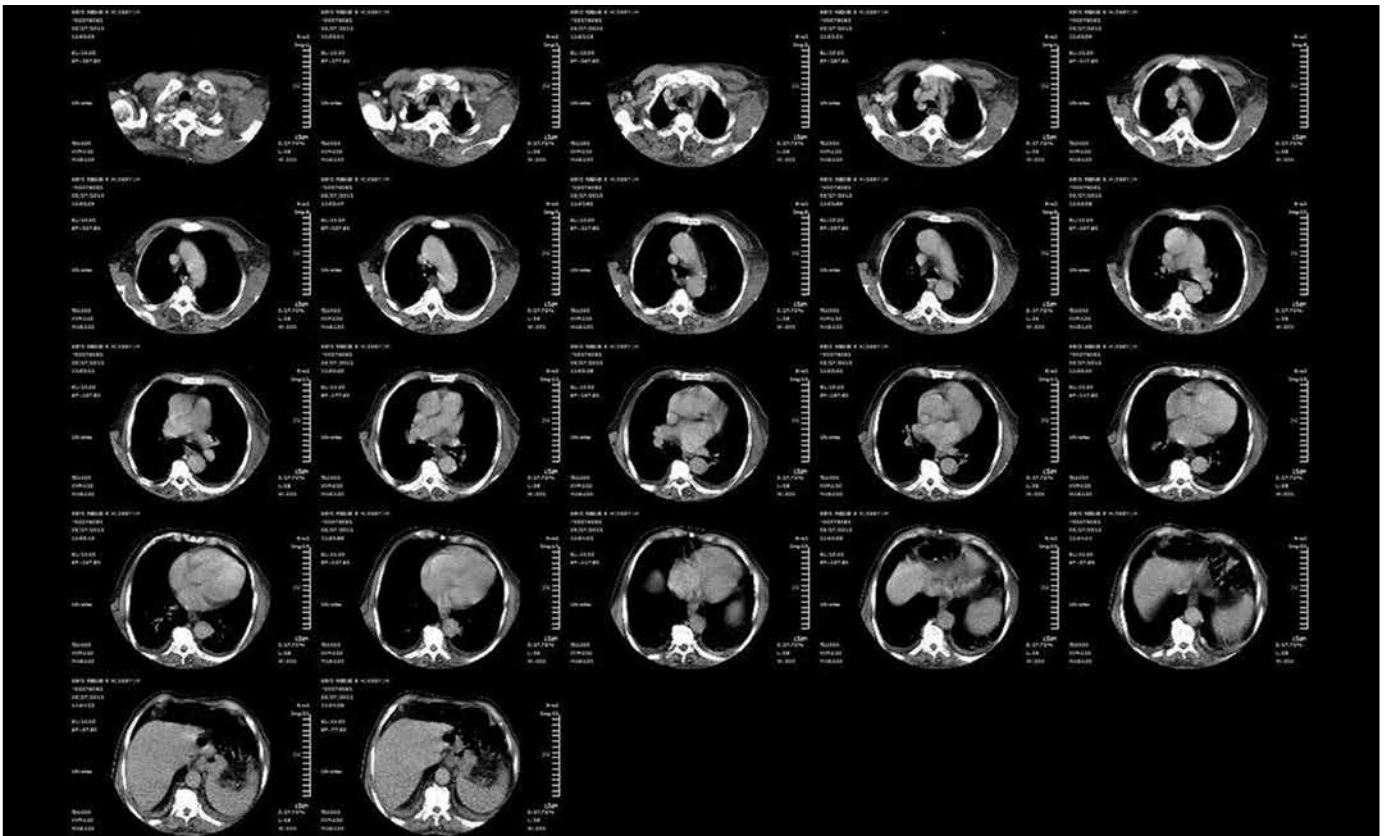


Figure 4. Chest CT scan with oral and intravenous contrast (several nodules with speculated and irregular margin in lungs are seen).

tient was vast ecchymoses on different parts of his body and hematuria. Most other cases reported previously also presented initially with ecchymoses, hematuria, and gastrointestinal hemorrhage [7–15].

The known risk factors making patients more susceptible to DIC include: older age, advanced tumor stage, and primary tumor necrosis [17]. Considering these risk factors our patient was at great risk of DIC.

The mechanism leading to DIC is still vague, very likely it is related to tumor cells that express procoagulant factors on their surface [18] or possess rich thromboplastin. The other theory is the production of some cytokines such as IL-6 and tumor necrosis factor [19, 20].

DIC is a fatal coagulopathy that needs a rapid supportive treatment to replace the hematologic factors in its life threatening episodes, but the main treatment is to diagnose the underlying disease and rectify it [21]. Investigations of the cause of DIC in our patient were highly suggestive for prostate cancer due to the high serum level of PSA and lesions seen in imaging of prostate. Biopsy and pathology can confirm the diagnosis but, in case of bleeding, can exacerbate the process of DIC or even initiate it by the introduction of thromboplastic substances into the blood stream [22, 23].

The treatment of this cancer is hormonal manipulation because testosterone is a stimulator of cancer-

ous cells [24]. So the source of hormones, especially testosterone, should be dispelled by orchiectomy or drugs such as flutamide, which competes with androgen receptors at the cellular level, and ketoconazole, which suppresses the adrenal production of testosterone [25, 26, 27]. In our patient, because of active bleeding, it was not possible to perform orchiectomy and only an LHRH agonist was prescribed together with chemotherapy with Taxotere every 21 days. In other similar cases, patients underwent hormone therapy, androgen blockade, and low oral anticoagulants along with chemotherapy especially during the hormone resistance phase [8, 9, 10, 29]. In Kato et al case report Docetaxel (Taxotere) was used to treat the afflicted tissues. In another report Ketoconazol with the dose of 400 mg every eight hours was used in emergency management of DIC in metastatic prostate cancer [30].

Disseminated carcinomatosis of the bone marrow derived from solid cancer with DIC has a very poor prognosis and despite all treatments these patients will die soon [31]. The patient till writing this report is still alive and treated by hormonal manipulation and chemotherapy.

In conclusion, malignancies should be considered in cases of DIC, especially in elderly men in whom no underlying cause can be found to explain it.

References

1. Levi M, de Jonge E, van der Poll T, Ten Cate H: Advances in the understanding of the pathogenetic pathways of disseminated intravascular coagulation result in more insight in the clinical picture and better management strategies. *Semin Thromb Hemost.* 2001; 27: 569–575.
2. Levi M. Disseminated intravascular coagulation in cancer patients. *Best Pract Res Clin Haematol.* 2009; 22: 129–36.
3. Duran I, Tannock IF. Disseminated Intravascular Coagulation as the Presenting Sign of Metastatic Prostate Cancer. *J Gen Intern Med.* 2006; 21: C6–C8.
4. de la Fouchardière C, Flechon A, Droz J–P. Coagulopathy in prostate cancer. *Neth J Med.* 2003; 61: 347–354.
5. Ojewola RW, Tijani KH, Jeje EA, Anunobi CC, Ogunjimi MA, Ezenwa EV, Ogunidiyi OS: Is extended biopsy protocol justified in all patients with suspected prostate cancer? *Niger J Clin Pract.* 2012; 15: 315–319.
6. Lin YE, Howard G Kynaston, Wen G Jiang. Bone metastasis in prostate cancer: Molecular and cellular mechanisms (Review). *Int J Mol Med.* 2007; 20: 103–111.
7. McKechnie J. Prostatic carcinoma presenting as a hemorrhagic diathesis after dental extraction. *Br Dent J.* 1989; 166: 295–296.
8. de la Torre RG, Gonzalez CIJ, Echevarria Foronda I, Zanabili Y, Alvarez Chao MT, Suarez del Villar R. Disseminated intravascular coagulation as presentation form of prostatic adenocarcinoma. *An Med Interna.* 2002; 19: 54–55.
9. Spector JI, Zimble H: Carcinoma of the prostate presenting as acute disseminated intravascular coagulation. *Can Med Assoc J.* 1987; 136: 570.
10. Ohtake N, Kurita S, Fukabori Y, Imai K, Yamanaka H, Nakata S, Sato J, et al: Clinical study on prostate cancer initially presenting with disseminated intravascular coagulation syndrome. *Hinyokika Kyo.* 1998; 44: 387–390.
11. Kato T, Yamamoto N, Matsuoka Y, Kuwata Y, Taoka T, Kazuki N, et al: Disseminated carcinomatosis of the bone marrow in two patients with prostate cancer. *Nihon Hinyokika Gakkai Zasshi.* 2011; 102: 28–33.
12. Minato N, Takada T, Koga M, Sugao H: Prostate cancer with disseminated carcinomatosis of bone marrow initially presenting with disseminated intravascular coagulation syndrome: a case report. *Hinyokika Kyo.* 2012; 58: 249–253.
13. Rabii R, Salomon L, Hodzinek A, Saint F, Cicco A, Chopin DK, Abbou CC. Prostatic adenocarcinoma revealed by disseminated intravascular coagulation and fibrinolysis. *Ann Urol (Paris).* 2002; 36: 269–271.
14. Hyman DM, Soff GA, Kampel LJ. Disseminated intravascular coagulation with excessive fibrinolysis in prostate cancer: a case series and review of the literature. *Oncology.* 2011; 81: 119–125.
15. Pinto F, Brescia A, Sacco E, Volpe A, Gardi M, Gulino G, Bassi P. Disseminated intravascular coagulation secondary to metastatic prostate cancer: case report and review of the literature. *Arch Ital Urol Androl.* 2009; 81: 212–214.
16. Deme D, Ragán M, Kovács L, Kalmár K, Varga E, Varga T, Rakonczai E: Metastatic prostate cancer complicated with chronic disseminated intravascular coagulopathy causing acute renal failure mimicking thrombotic thrombocytopenic purpura and hemolytic uremic syndrome: pathomechanism, differential diagnosis and therapy related to a case. *Magyar Onkológia.* 2010; 54: 351–357.
17. Sallah S, Wan JY, Nguyen NP, Hanrahan LR, Sigounas G: Disseminated intravascular coagulation in solid tumors: clinical and pathologic study. *Thromb Haemost.* 2001; 86: 828–833.
18. Levi M. Cancer and DIC. *Haemostasis.* 2001; 31: 47–48.
19. Poll T van der, Buller HR, Cate H ten, Wortel CH, Bauer KA, van Deventer SJH, et al. Activation of coagulation after administration of tumor necrosis factor to normal subjects. *N Engl J Med.* 1990; 322: 1622–1627.
20. Nakashima J, Tachibana M, Ueno M, Baba S, Tazaki H. Tumor necrosis factor and coagulopathy in patients with prostate cancer. *Cancer Res.* 1995; 55: 4881–4885.
21. Adamson AS, Francis JL, Witherow RO, Snell ME. Coagulopathy in the prostate cancer patient: prevalence and clinical relevance. *Ann R Coll Surg Engl.* 1993; 75: 100–104.
22. Harvey MH, Osborn DE, Hutchinson RM. Disseminated intravascular coagulation following transrectal prostatic biopsy. *Br J Urol.* 1987; 59: 363–364.
23. Navarro M, Ruiz I, Martín G, Cruz JJ. Patient with disseminated intravascular coagulation as the first manifestation of adenocarcinoma of the prostate, Risks of prostatic biopsy. *Prostate Cancer Prostatic Dis.* 2006; 9: 190–191.
24. Shahinian VB, Kuo YF, Freeman JL, Orihuela E, Goodwin JS: Increasing use of gonadotropin-releasing hormone agonists for the treatment of localized prostate carcinoma. *Cancer.* 2005; 103: 1615–1624.
25. Bern MM. Coagulopathy, following medical therapy, for carcinoma of the prostate. *Hematology.* 2005; 10: 65–68.
26. Trachtenberg J, Pont A. Ketoconazole therapy for advanced prostate cancer. *Lancet.* 1984; 2: 433–435.
27. Chakrapee–Sirisuk S, Amornpichetkul K, Visudhiphan S, Sangruchi T, Srimuninnimit V, Sinlarat P. Ketoconazole and Flutamide in the treatment of disseminated intravascular clotting from prostate cancer: a case report and review. *J Med Assoc Thai.* 2001; 84: 1495–1501.
28. Avances C, Oumaya C, Granger V, Dubon O, Gris JC, Culine S, Costa P. Prostate cancer and acute disseminated intravascular coagulation. Therapeutic management based on three cases. *Prog Urol.* 2003; 13: 308–312.
29. Duran I, Tannock IF. Disseminated intravascular coagulation as the presenting sign of metastatic prostate cancer. *J Gen Intern Med.* 2006; 21: C6–8.
30. Lowe FC, Somers WJ. The use of ketoconazole in the emergency management of disseminated intravascular coagulation due to metastatic prostatic cancer. *J Urol.* 1987; 137: 1000–1002.
31. Chargari C, Vedrine L, Bauduceau O, Le Moulec S, Fayolle M, Ceccaldi B, Houlgatte A: Prostate cancer and disseminated intravascular coagulation: review of the literature. *Prog Urol.* 2008; 18: 9. ■