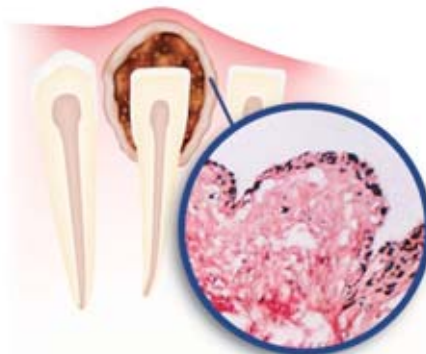


A Pigmented Dentigerous Cyst in a Patient with Multiple Dentigerous Cysts of the Jaws: A Case Report

Shokoufeh Shahrabi Farahani, DDS, MS;
Mohammadtaghi Lotfalian, DDS, MS



Abstract

Aim: The aim of this article is to report an unusual and interesting case of non-syndromic multiple dentigerous cysts of the maxilla and mandible associated with melanin pigment and melanocytes in the epithelial lining in one of the cysts. In addition, embryologic aspect and origin of melanocytes are briefly discussed.

Background: Dentigerous cysts are the second most common odontogenic cysts after radicular cysts. They are usually solitary with multiple cysts reported on occasion in association with syndromes. While melanocytes and melanin-pigment are widely distributed in the skin, the nervous system, certain types of mucosa, uveal tract, and other areas, they are not normally present within bone in mammals.

Report: A 37-year-old Iranian male was referred to an oral surgeon by his dentist for evaluation and treatment of multiple cyst-like radiolucent lesions around the crowns of some unerupted permanent teeth in both maxillary and mandibular anterior areas. The biopsy revealed numerous granules of melanin-pigment distributed throughout the epithelial lining of one of these cysts in addition to the characteristic histopathologic features of a dentigerous cyst. Histochemical analysis confirmed the pigment was melanin, and many of the cells containing melanin were immunohistochemically positive for s-100 protein.

Summary: Although the specific origin and pathologic significance of the melanocytes described here cannot be explained, it may be of interest for future investigations.

Keywords: Multiple dentigerous cysts, melanin, pigment, melanocytes, odontogenic cyst, jaws

Citation: Shahrabi Farahani S, Lotfalian M. A Pigmented Dentigerous Cyst in a Patient with Multiple Dentigerous Cysts of the Jaws: A Case Report. J Contemp Dent Pract 2007 July;(8)5:085-091.

Introduction

Dentigerous cysts are the second most common odontogenic cysts after radicular cysts. They are usually solitary with multiple cysts reported on occasion in association with syndromes such as basal cell nevus syndrome, cleidocranial dysplasia, and mucopolysaccharidosis.^{1,2}

Melanocytes and melanin-pigment are widely distributed in the skin, the nervous system, certain types of mucosa, uveal tract, and other areas but are not normally present within bone in mammals.^{3,4} Melanin-pigmented jaw odontogenic lesions are rare, and few cases have been reported.³⁻⁸

The present paper reports an unusual and interesting case of non-syndromic multiple dentigerous cysts of both the maxilla and mandible associated with melanin pigment and melanocytes in the epithelial lining in one of the cysts. In addition, the embryologic aspect and origin of melanocytes are briefly discussed.

Case Report

A 37-year-old Iranian male was referred to an oral surgeon by his dentist for evaluation and treatment of multiple cyst-like radiolucent lesions around the crowns of some unerupted maxillary and mandibular permanent teeth. Except for a slight swelling of the anterior region of the mandible, the clinical examination was unremarkable and routine laboratory tests were within normal limits. The past medical history was noncontributory and the patient was in good

health. The overlying mucosa was intact and normal in color.

The panoramic radiograph revealed multiple well-circumscribed radiolucent cystic lesions surrounding the crowns of maxillary canines, the right mandibular canine, the left mandibular lateral incisor, and the lateral aspect of left mandibular canine (Figure.1).

A clinical diagnosis of suspected dentigerous cyst was made. Upon surgical resection of the lesions including unerupted teeth, some of the cyst wall-like tissues were torn. The surgery was performed in two separate sessions.

Upon histological examination almost all specimens were similar and consisted of strips of loose fibrous tissue lined on one surface with cuboidal or flattened cells and degenerating squamous epithelium. In the epithelial lining of a cyst associated with the right maxillary canine some mucous producing cells was also noted. A moderate inflammatory infiltrate consisting of lymphocytes, plasma cells, and histiocytes was seen in the connective tissue. Two unusual histologic features of interest were fine granules and coarse aggregates of dark brown-pigment distributed throughout the entire epithelial lining of the cyst related to the unerupted right mandibular canine (Figure 2).

A few pigments and sebaceous glands were also seen in the connective tissue of the mentioned

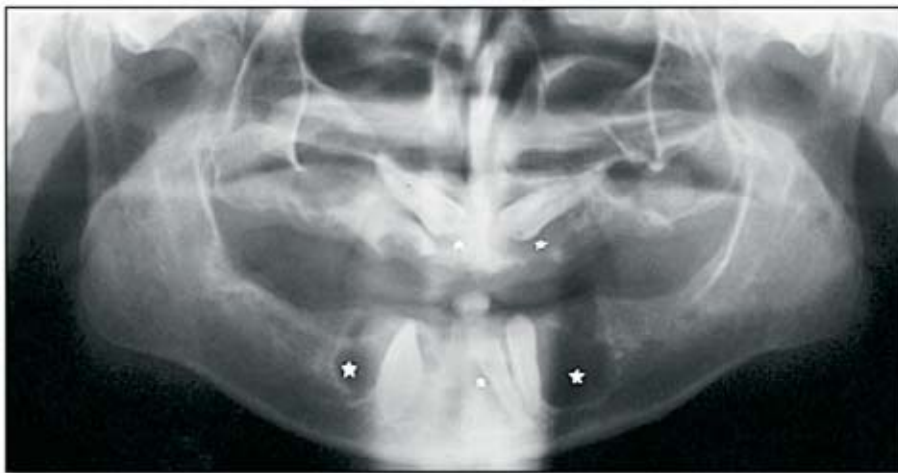

Figure 1. Preoperative panoramic radiograph showing radiolucencies (stars) surrounding unerupted maxillary canines, mandibular canines, and the left mandibular lateral incisor.

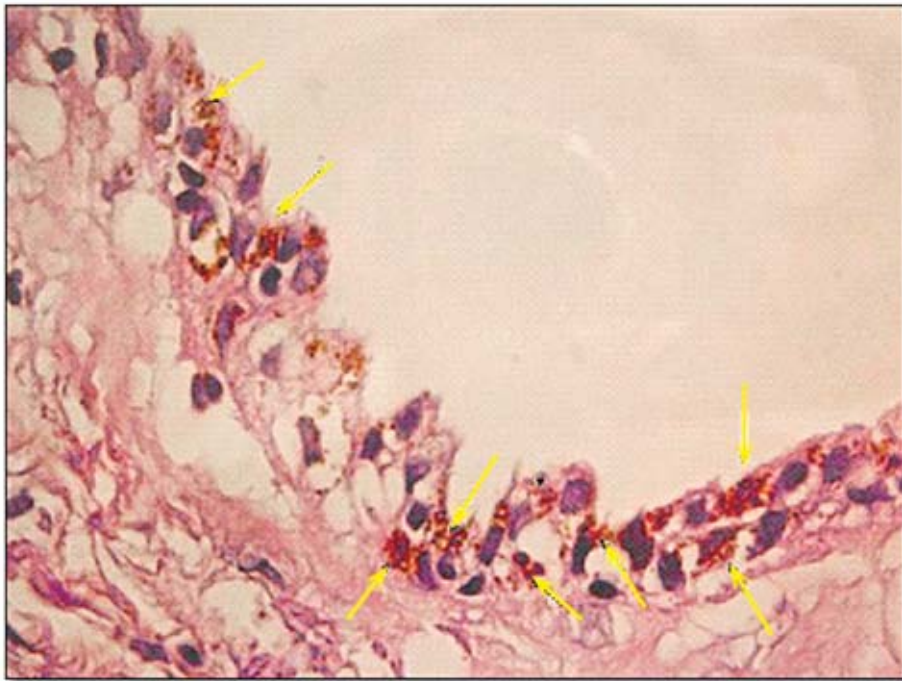

Figure 2. Microscopic findings of a cyst lining related to an unerupted right mandibular canine showing numerous dark brown-stained granules (arrows) throughout the entire epithelium (H&E, X400).

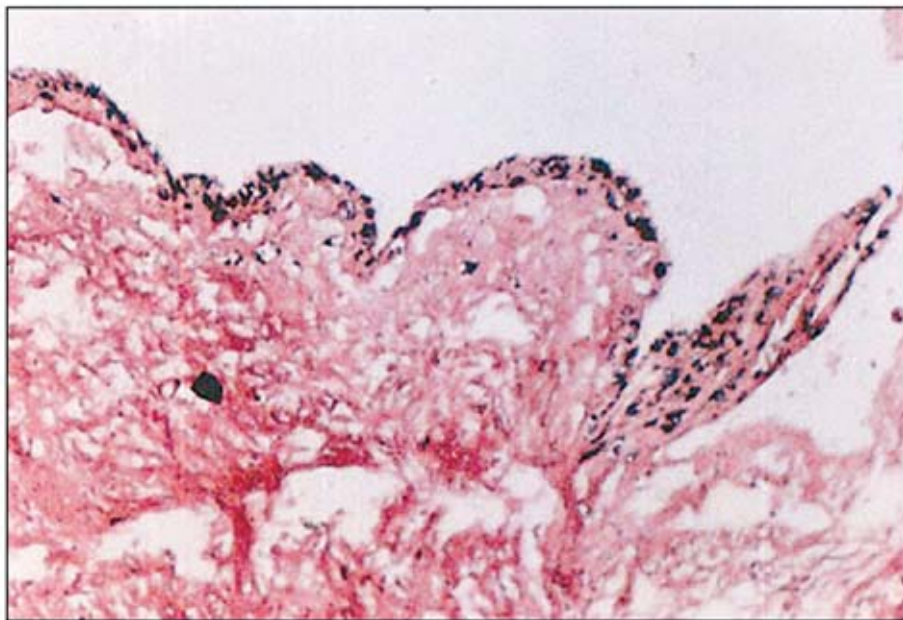


Figure 3. Cyst lining showing strongly positive evidence of melanin pigment in the epithelium (Masson-Fontana's staining, X200).

cyst. Histochemical examination using Masson-Fontana's staining for melanin (Figure 3) and bleaching with hydrogen peroxide and potassium permanganate solution confirmed the pigment was melanin.

The cells containing melanin pigment were immunohistochemically positive for 1:2000 dilution, Polyclonal s-100 protein (Dako, Santa Barbara, CA, USA) (Figure 4).

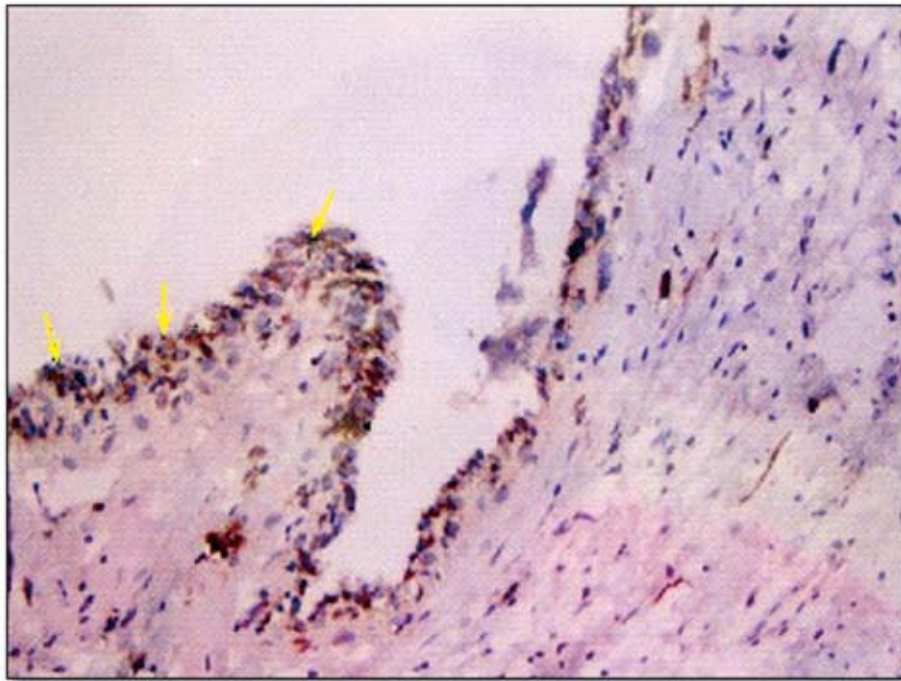


Figure 4. S-100 protein positive cells (arrows) in the lining epithelium (Immunohistochemical stain after bleaching, X200).

Discussion

Dentigerous cysts are benign odontogenic cysts associated with the crowns of permanent teeth.² Multiple cysts have been reported in patients with syndromes such as basal cell nevus syndrome, cleidocranial dysplasia, and mucopolysaccharidosis as well as Maroteaux-Lamy syndrome and Hunter's syndrome.^{2,9,10} Multiple cysts have also been reported after prolonged concurrent use of cyclosporine A and calcium channel blockers¹¹ as well as other skeletal defects,¹² gingival hyperplasia, and abnormality in development and eruption of teeth are the most common features shared by most of these syndromes.¹¹

Our patient had multiple dentigerous cysts in both the maxilla and mandible but was a healthy man with no abnormal physical or laboratory findings suggesting any syndromes. Up to now, few cases of multiple dentigerous cysts involving both the maxilla and mandible in nonsyndromic patients have been reported.^{9,13}

Melanin pigment and/or melanocytes is a rare component of odontogenic cysts. It has been reported in association with calcifying odontogenic cysts, gingival cysts, odontogenic keratocysts, botryoid odontogenic cysts, and

lateral periodontal cysts^{7,14-21} and has also been noted in some odontogenic tumors.^{4-6,8,22} The first case of a pigmented dentigerous cyst was reported by Takada and Yamamoto.³ Warter et al.²³ reported the case of a dentigerous cyst associated with an adenomatoid odontogenic tumor containing melanocytes and melanin-laden epithelial cells but were not able to exclude the possibility their case may have been an adenomatoid odontogenic tumor with a prominent cystic structure; so, to our knowledge, the present case is the second report of a dentigerous cyst in the cyst wall and also the first one in a patient with multiple cysts.

The origin of the melanocytes in odontogenic lesions is speculative, since the presence of melanocytes in the oral mucosa is not uncommon and the dental lamina originates from the primitive oral lining, the occasional presence of melanocytes in odontogenic lesions must be expected.²³ Lawson et al.²⁴ have studied the distribution of melanocytes in the dental primordium of human fetuses, 12 to 18 weeks of gestation, and found melanocytes within the dental lamina or tooth bud in three of 11 Caucasians and in all six Negro fetuses.²⁴ Previous studies have suggested melanin-

producing cells migrate rapidly after neural-crest morphogenesis is completed, which has been estimated to occur at approximately four weeks of fertilization age;²⁴ this means the presence of melanocytes in the dental primordium points to a contribution by the neural crest to the formation of the tooth in mammals. Such evidence of melanocytes in the dental anlage may also explain the histogenesis of melanin-pigment in the odontogenic lesions. Although the pathologic significance of melanocytes in odontogenic tumors and cysts is still unclear, most of the cases of pigmented odontogenic lesions reported have been mixed tumors with the induction of dental hard tissues or prominent calcification. However, when considering the present case, no pathologic significance of melanocytes in odontogenic cysts can be concluded.

The pigmentation in odontogenic lesions has been considered to represent racial pigmentation; since most patients reported were Asian or

Black.^{15,17-21} However, the limited number of cases does not give statistical value to the data.

Another possible explanation for presence of melanin within the bone is passage of melanocytes through the mesenchyme, not within the ectoderm due to failure to complete their migration from the neural crest to periphery.²⁴

In spite of the more superficial position of the present case in bone a thin layer of cortical bone remained, so the possible connection of reactive hyperplastic melanocytes of overlying oral mucosa with the epithelial lining of the cyst can be ruled out.

Summary

Although the specific origin and pathologic significance of the melanocytes described here cannot be explained, it may be of interest for future investigations.

References

1. Shah N, Thuan H, Beale T. Spontaneous regression of bilateral dentigerous cysts associated with impacted mandibular third molars. *Br Dent J* 2002; 192(2): 75-76.
2. Ustuner E, Fitoz S, Atasoy C, Erden I, Akyar S. Bilateral maxillary dentigerous cysts: A case report. *Oral Surg Oral Med Oral Pathol Oral Radiol Endod* 2003; 95(5): 632-5.
3. Takada Y, Yamamoto H. Case report of a pigmented dentigerous cyst and a review of the literature on pigmented odontogenic cysts. *J Oral Sci* 2000; 42(1): 43-46.
4. Melanin pigment in ghost cells of a complex odontoma Takada Y, Yamamoto H. Melanin pigment in ghost cells of a complex odontoma. *J Nihon Univ Sch Dent* 1998; 31: 502-506.
5. Takada Yasunori. Melanocytes in malignant ameloblastoma, case report. *Pathology international* 1996; 46: 777-781.
6. Aldred MJ, Gray AR. A pigmented adenomatoid odontogenic tumor. *Oral Surg Oral Med Oral Pathol* 1990; 70(1): 86-9.
7. Macked RI, Fanibanda KB, Soames JV. A pigmented odontogenic keratocyst. *Br J Oral Maxillofac Surg* 1985; 23: 216-219.
8. Takada Y, Soto H, Satoh M, Nakamura S, Yamamoto H. Pigmented ameloblastic fibrodentinoma: a novel melanin-pigment intraosseous odontogenic lesion. *Virchows Arch* 2000; 437(4): 454-8.
9. Sheinkopf DE, Sadowsky D, Seife B. Multiple dentigerous cysts in several facial bones. *Oral Surg Oral Med Oral Pathol* 1979; 48(5): 492.
10. Roberts MW, Barton NW, Constantopoulos G, Butler DP, Donahue AH. Occurrence of multiple dentigerous cysts in a patient with the Maroteaux-Lamy syndrome (mucopolysaccharidosis, type V). *Oral Surg Oral Med Oral Pathol* 1984; 58(2): 169-75.
11. De Biase A, Ottolenghi L, Polimeni A, Benvenuto A, Lubrano R, Magliocca FM. Bilateral mandibular cysts associated with cyclosporine use: a case report. *Pediatr Nephrol* 2001; 16: 993-5.
12. Smith NH. Multiple dentigerous cysts associated with arachnodactyly and other skeletal defects. Report of a case. *Oral Surg Oral Med Oral Pathol* 1968; 25(1): 99-107.
13. Carr MM, Anderson RD, Clarke KD. Multiple dentigerous cysts in childhood. *J Otolaryngol* 1996; 25(4): 267-70.

14. Takada Y, Kuroda M, Suzuki A, Fujioka Y. Pigmented variant of calcifying odontogenic cyst. Report of an additional case and review of the literature. *Acta Pathol. Jpn* 1985; 35: 1023-1027.
15. Buchner A, David R, Carpenter W, Leider A. Pigmented periodontal cyst and other pigmented odontogenic lesions. *Oral Dis* 1996; 2(4): 299-302.
16. Soamaes JV. A pigmented calcifying odontogenic cyst. *Oral Surg Oral Med Oral Pathol* 1982; 53: 395.
17. Grand NG, Marwah AS. Pigmented gingival cyst. *Oral Surg Oral Med Oral Pathol* 1964; 17: 635-639.
18. Browne RM. The odontogenic keratocyst. Histologic features and their correlation with clinical behavior. *Br Dent J* 1977; 131: 249-259.
19. Brannon RB. The odontogenic keratocyst. A clinicopathologic study of 312 cases. Part 2. *Oral Surg Oral Med Oral Pathol* 1977; 43: 233-255.
20. Takada Y, Kuroda M, Suzuki A, Fujika Y. Melanocytes in odontogenic keratocyst. *Acta Pathol. Jpn* 1985; 35: 899-903.
21. Altini M, Shear M. The lateral periodontal cyst: an update. *J Oral Pathol Med* 1992; 21: 245-250.
22. Takada Y, Suzuki A, Kuroda M, Yamazaki Y. Melanin-pigment in complex odontoma. *Int J Oral Maxillofac Surg* 1987; 16(2): 222-6.
23. Warter A, George-Diolombi G, Chazal M, Ango A. Melanin in a dentigerous cyst and associated adenomatoid odontogenic tumor. *Cancer* 1990; 66: 786-788.
24. Lawson W, Abasi IF, Zak FG, Brooklya NY. Studies on melanocytes.V.The presence of melanocytes in the human dental primordium: An explanation for pigmented lesions of the jaws. *Oral Surg* 1976; 42(3): 375-380.

About the Authors

Shokoufeh Shahrabi Farahani, DDS, MS



Dr. Shahrabi Farahani an Assistant Professor and Chair of the Department of Oral and Maxillofacial Pathology of the School of Dentistry at the Shahid Sadoughi University of Medical Sciences and Health Services in Yazd, Iran. She is also a member of the Research Committee of the dental school and has authored and presented several papers at International congresses. Dr. Shahrabi Farahani has a passion for art and is skillful in Iranian painting styles such as Miniature, Illumination as well as carpet design.

e-mail: shahrabi@ut.ac.ir, rshahrabi@ut.ac.ir or Shokoufeh_shahrabi@hotmail.com

Mohammadtaghi Lotfalian, DDS, MS



Dr. Lotfalian is an Oral and Maxillofacial Surgeon. He provides clinical services at the Bozorgmehr Dental Clinic of Tehran University and he also is in private practice.

Acknowledgments

We would like to thank Mr. M. Homaifar and Mrs. Vaziri for their kindly preparation and staining of the histopathological sections.