

Examination of the Topical Effect of the Combination of *Plantago ovata* and Vinegar on the Improvement of Rural Cutaneous Leishmaniasis Lesions

Mohammad Ebrahimzadeh Ardakani¹, Majid Emtiazy², Mohammad Hassan Lotfi³, Mehrdad Mousavi⁴

¹Department of Dermatology, Shahid Sadoughi University of Medical Sciences, Yazd, Iran, ²Department of Persian Medicine, Shahid Sadoughi Hospital, Shahid Sadoughi University of Medical Sciences, Yazd, Iran, ³Department of Biostatistics and Epidemiology, School of Health, Social Determinants of Health Research Center, Shahid Sadoughi University of Medical Sciences, Yazd, Iran, ⁴Department of Persian Medicine, Shahid Sadoughi University of Medical Sciences, Yazd, Iran

Abstract

Background: The present study aimed at investigating the topical effect of the combination of *Plantago ovata* and vinegar on the improvement of rural cutaneous leishmaniasis lesions.

Materials and Methods: The present randomized double-blind controlled clinical trial was performed on 42 patients with rural skin leishmaniasis. In the case group, in addition to injecting glucantime into the lesion according to the latest national instructions, a combination of *P. ovata* and vinegar was applied topically twice a day for 8 weeks. In the control group, only glucantime injection into the lesion was performed for 8 weeks according to the latest national guidelines. At the end of the 1st, 2nd, 3rd, 4th, 8th, and 12th weeks after the intervention, the lesion area and improvement were evaluated and recorded.

Results: The results of the present study indicated the lesion area in the case group with the mean of 0.35 ± 0.39 cm and 0.18 ± 0.27 cm in the 8th and 12th weeks, respectively was significantly less than that of the control group with the mean of 0.64 ± 0.78 cm and 0.56 ± 0.44 , respectively ($P < 0.05$). Twelve weeks after the intervention, 84.1% of the lesions in the case group and 65.9% of the lesions in the control group were completely improved ($P < 0.05$).

Conclusion: According to the results of the present study, the improvement of leishmaniasis lesion with the topical application of the combination of *P. ovata* and vinegar was significantly more than that of the control group in the 8th and 12th weeks after the intervention.

Keywords: Cutaneous leishmaniasis, glucantime, *Plantago ovata*, vinegar

Address for correspondence: Dr. Mehrdad Mousavi, Department of Persian Medicine, Shahid Sadoughi University of Medical Sciences, Yazd, Iran.
E-mail: dr_smmmd@yahoo.com

Submitted: 28-Nov-2021; **Revised:** 05-Jan-2022; **Accepted:** 19-Jan-2022; **Published:** 25-Feb-2023

INTRODUCTION

Leishmaniasis is one of the most significant health problems in Iran and the world and infects a large number of people every year.^[1,2] Numerous leishmaniasis lesions including cutaneous, visceral, and mucosal leishmaniasis have been observed in humans.^[3] The disease is caused by various species of *Leishmania* parasites that escape from the lethal system of macrophages and survive and multiply inside

them.^[1] Cutaneous leishmaniasis is the most common type of leishmaniasis and has the widest geographical distribution. The carrier of the disease in the wet or rural type is phlebotomus papatasi and in the dry or urban type is phlebotomus sergenti. The reservoir of the disease is human and rodents in the dry and wet types, respectively. The latency period is shorter in the wet type.^[4] Iran is one of the dominant centers for cutaneous leishmaniasis. The disease is endemic in some regions of the

This is an open access journal, and articles are distributed under the terms of the Creative Commons Attribution-NonCommercial-ShareAlike 4.0 License, which allows others to remix, tweak, and build upon the work non-commercially, as long as appropriate credit is given and the new creations are licensed under the identical terms.

For reprints contact: WKHLRPMedknow_reprints@wolterskluwer.com

How to cite this article: Ebrahimzadeh Ardekani M, Emtiazy M, Lotfi MH, Mousavi M. Examination of the topical effect of the combination of *Plantago ovata* and vinegar on the improvement of rural cutaneous leishmaniasis lesions. Adv Biomed Res 2023;12:32.

Access this article online

Quick Response Code:



Website:
www.advbiores.net

DOI:
10.4103/abr.abr_376_21

country. Rural or wet leishmaniasis is observed in most cases, especially the regions involved in this project.^[2,5,6]

Various drug therapies and treatment approaches have been employed for this disease. The most effective treatment in this regard is the use of pentavalent antimonials (sodium stibogluconate, pentostam, meglumine antimoniate, glucantime), which not only are expensive and rare but also have relatively severe complications and a long duration of treatment. Moreover, the therapeutic effect of diverse products is different, and drug resistance has reduced their therapeutic effect in recent years.^[7] In addition, their use has been limited recently due to cardiac toxicity, liver toxicity, and a number of other complications.^[8-10]

The recent approach of the medical world regarding the use of natural products in the prevention and treatment of diseases has caused the World Health Organization to formulate 5-year strategies to encourage all countries to review their traditional medicine schools and move towards using their capacities.^[11]

In the old books and texts of traditional Persian medicine (TPM), leishmaniasis is mostly referred to as ulcers or skin lesions that secrete nectarous liquid, which are named Balkhieh, Kheyroonieh.^[12]

In this regard, as some researchers in TPM believe that this disease arises from biliary blood, in addition to the topical treatment, a number of medicines including moderate temperament, sour syrups such as barberry syrup, rhubarb syrup, lemon syrup, verjuice syrup as well as apple juice, camphor, rhubarb water with sugar, sandalwood syrup, and sour pomegranate juice have been cited in the TPM sources.^[12,13]

The effect of herbs on leishmaniasis has been examined in various studies, and the anti-leishmaniasis effects of some herbs and herbal compounds such as a number of Coumarins, Quinolines, Terpenes, Alkaloids, Coumarins, Flavonoids, Lactones, Chalcones, Tetralones, and Saponins have been proven in the literature.^[12] The effectiveness of various herbs on promastigotes and the treatment of leishmaniasis in animal and human models have also been investigated *in vitro*. Some of the mentioned herbs with anti-promastigote effect consist of *Vinca major*, *Cassia fistula* fruit, Thyme, *Peganum harmala* and *Myrtus*, mountain tea and *Mespilus germanica* leaves, *Artemisia aucheri*, asafoetida, cotton boll, Aloe vera, barberry.^[12,14-16]

Furthermore, the combination of *Plantago ovata* and vinegar is considered useful in relieving edema and gout in Tohfa Tul Momineen Akseer Azam, Tebb-e-akbari, and the Canon of Medicine, and other books.^[13,17]

Regarding the effect of *P. ovata* and vinegar, only one study was performed on mice and indicated that this combination can provide the best therapeutic effect, the main part of which is related to vinegar and *P. ovata* has a supportive and maintenance role.^[18]

Considering the lack of any clinical study on humans, the positive results of the previous study, and the significance of providing a satisfactory treatment for these patients, the present study aimed at investigating the topical effect of the combination of *P. ovata* and vinegar on the improvement of skin leishmaniasis lesions.

MATERIALS AND METHODS

The present study was a double-blind randomized controlled clinical trial. The study population included all patients with rural cutaneous leishmaniasis that referred to the skin diseases and leishmaniasis research centers and clinics located in rural centers of East Isfahan and Ardakan plain center of Yazd during 2018–2019.

In the clinical ward, a direct smear was performed for the patients that referred to the relevant centers and were suspected of a new case of acute cutaneous leishmaniasis. If the smear test was positive and the inclusion criteria were met, the patients were included in the study using the convenience nonprobability sampling technique. Therefore, 42 patients (21 in each group) participated in the study.

Inclusion criteria consisted of confirmed cutaneous leishmaniasis proved by smear, the age range of 6–60 years, the lesion size of <4 cm, the disease course of <12 weeks, no lesion on the face, no history of taking other anti-leishmaniasis drugs over the last 4 weeks, lack of pregnancy and breastfeeding, no history of severe skin diseases such as eczema, psoriasis, or chronic dermatitis of unknown origin, lack of any chronic and malignant diseases (undergoing chemotherapy), four or less lesions in the body, and no travel history over the last 6 months to other leishmaniasis-endemic areas. In addition, if the leishmaniasis type was complex and the patient received a treatment for leishmaniasis over the past month, had complications such as symptoms of mucosal leishmaniasis, had regional adenopathy larger than 1 cm in size, had satellite or sporotrichoid lesions, and had a history of drug allergy to antimonial compounds, they were excluded from the study and were replaced by another sample.

After obtaining the code of ethics from Yazd University of Medical Sciences (IR.SSU.REC.1398.136), the clinical trial code (IRCT20191221045845N1), and the written consent from eligible patients, demographic and clinical information of patients including age, sex, location of the lesions, number of lesions, type of lesions, and the lesion area were recorded.

Medicine preparation

P. ovata plant was purchased from farms around Isfahan, was approved by the expert in medicinal plants of Shahreza University, and was registered. In addition, vinegar was prepared with an acid concentration of about 5% from grapes grown in gardens around Shahreza. Equal amounts of the ground *P. ovata* powder and vinegar were mixed and kept for about 48 h until the combination had an appropriate consistency. Microbial testing, determination of acidity, and determination

of phenol content were performed for the prepared compound. The placebo was also prepared by a pharmacist in such a way that it was similar to the combination of *P. ovata* and vinegar in terms of the shape, consistency, color, and smell and was placed in the same packages. Then, the packages were coded with codes A and B, and the patients chose a package without knowing the contents of each package, as a result of which the patients were divided into two groups of 21.

Intervention

In the first group (case group), the standard treatment of leishmaniasis was performed according to the latest national guidelines. Thus, glucantime (meglumine antimonite 8.5% containing 85 mg/ml pentavalent antimony) was injected into the lesion at a rate of 0.2 to 0.5 cc in the upper and middle parts of the lesion base until the complete whitening of the lesion. The mentioned intervention was performed one to three times a week for 8 weeks. In addition, the topical administration of the combination of *P. ovata* and Vinegar was used twice a day until the complete improvement or 8 weeks. In the second group (control group), only glucantime was injected into the lesion according to the latest national guidelines. In addition, similar to the case group, placebo was used twice a day until the complete improvement or 8 weeks [Figure 1].

It should be noted that the administration of drug continued until the complete epithelialization of the lesion or up to 8 weeks after treatment. Moreover, all therapeutic interventions were performed by a skilled dermatologist that was not informed of the type of the drug interventions.

At the end of the 1st, 2nd, 3rd, 4th, 8th, and 12th weeks after the intervention, the lesion area and the degree of lesion improvement were evaluated and recorded. The improvement degree of 100%, the improvement degree of 50%–99%, and the improvement degree of <50% till the 12th week were regarded as complete, partial, and nonimprovement.

Finally, the collected data was entered into SPSS software (version 25; SPSS Inc., Chicago, Ill., USA). Data were presented as means \pm standard deviation or frequency (percentage). At the level of inferential statistics, tests such as Chi-squared test, independent samples *t*-test, and univariate analysis test were used by adjusting confounding variables such as the primary lesion area, sex, age, the location of the lesions, and the type of lesions. The significance level of <0.05 was considered in all analyses.

RESULTS

In the present study, 15 (71.4%) females and 6 (28.6%) males with the mean age of 25.00 ± 17.56 years were in the case group (receiving the combination of *P. ovata* and vinegar), and 10 (47.6%) females and 11 (52.4%) males with the mean age of 23.84 ± 13.49 years were in the control group ($P > 0.05$). The number of lesions in each group was 44 cases such that 56.8%, 38.6%, and 4.5% of lesions were respectively in the upper limbs, lower limbs, and body in the case group and 61.4%,

36.4%, and 2.3% of lesions were respectively in the upper limbs, lower limbs, and body in the control group ($P = 0.802$). In addition, more than 80% of the lesions in both groups were ulcers ($P = 0.984$) [Table 1].

Prior to the intervention, the mean lesion area did not differ significantly between the two groups ($P = 0.969$). Moreover, the mean lesion area from the 1st to 4th weeks was not significantly different between the two groups by adjusting the confounding variables such as age, sex, the primary lesion area, the location of lesions, and the type of lesions ($P > 0.05$). In the 8th and 12th weeks, the lesion area in the case group with the mean of 0.35 ± 0.39 cm and 0.18 ± 0.27 cm, respectively was significantly less than that of the control group with the mean of 0.64 ± 0.78 cm and 0.56 ± 0.44 , respectively ($P < 0.05$) [Table 2].

In addition, the process of lesion improvement in each type of lesion was not significantly different such that both groups' lesions were significantly improved in the 8th and weeks. However, nodule lesions seemed to be associated with less improvement (up to the 4th week) in the case group as compared with the control group although the mentioned difference was not significant ($P > 0.05$) [Figure 2].

Finally, it was indicated that 84.1% of the lesions in the case group and 65.9% of the lesions in the control group were completely improved. In the case group, the number of completely improved cases after the treatment was 5, 17, and 15 lesions in the case group and 0, 25, and 4 lesions in the control group in the 4th, 8th, and 12th weeks, respectively. In addition, the partial improvement was 22.4% and 34.1% in the case and control groups, respectively. Moreover, only 4.5% of patients in the case group had the improvement of less than 50% (nonimprovement) ($P < 0.05$) [Table 3].

Table 1: Basic characteristics of patients in the two groups

Variables	Case group (%)	Control group (%)	P
Sex			
Female	15 (71.4)	10 (47.6)	0.116
Male	6 (28.6)	11 (52.4)	
Age; year	25.00 \pm 17.56	23.84 \pm 13.49	0.729
Location of the lesions*			
Upper limbs	25 (56.8)	27 (61.4)	0.802
Lower limbs	17 (38.6)	16 (36.4)	
Body	2 (4.5)	1 (2.3)	
Number of the lesions			
Upper limbs	1.88 \pm 1.25	2.38 \pm 1.32	0.393
Lower limbs	2.63 \pm 1.33	1.63 \pm 0.52	
Body	2 \pm 0.72	1 \pm 0.71	
Type of the lesions*			
Ulcer	38 (86.4)	39 (88.6)	0.984
Plaque	1 (2.3)	1 (2.3)	
Nodule	4 (9.1)	3 (6.8)	
Papule	1 (2.3)	1 (2.3)	

*A patient may have more than one lesion

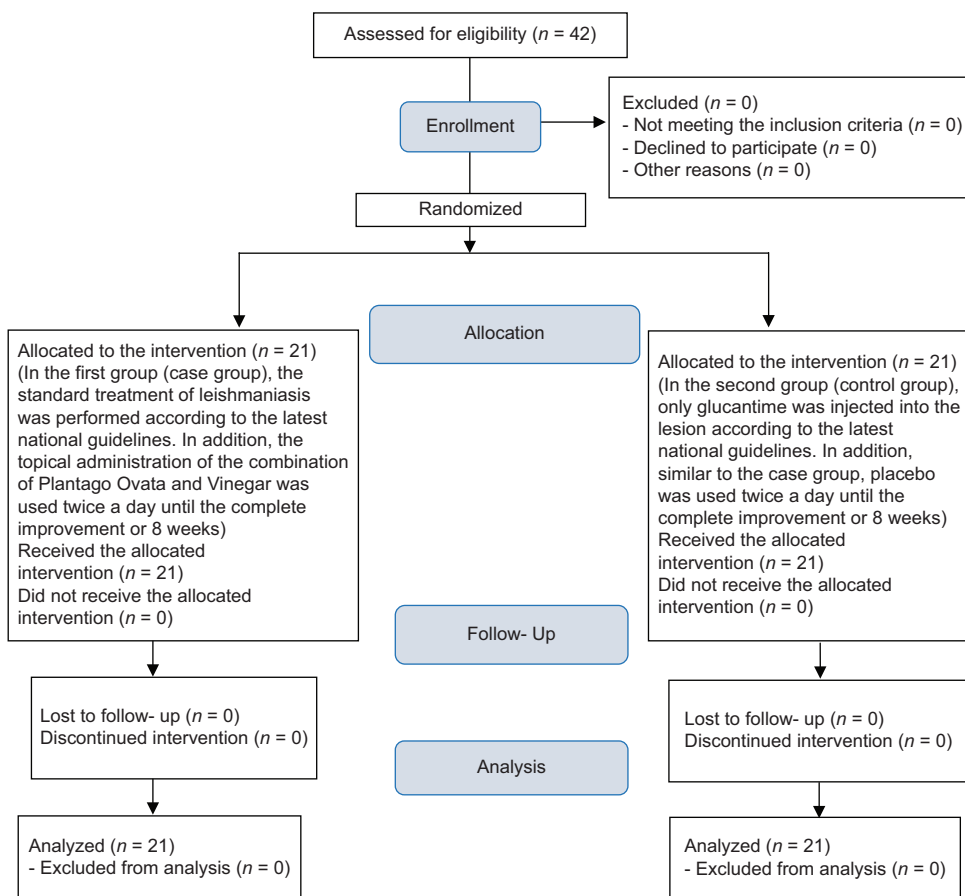


Figure 1: Consort flowchart of patients

Table 2: Comparison of patients' lesion area in the two groups

The lesion area	Case group	Control group	P*
Before intervention	3.02±0.91	3.01±0.75	0.969
One week after the intervention	3.16±0.92	2.94±0.77	0.236
Two weeks after the intervention	2.64±1.03	2.62±0.80	0.898
Three weeks after the intervention	2.20±0.89	2.23±0.86	0.904
Four weeks after the intervention	1.45±0.86	1.80±0.85	0.053
Eight weeks after the intervention	0.35±0.39	0.64±0.78	0.038
Twelve weeks after the intervention	0.18±0.27	0.56±0.44	0.004
P**	<0.001	<0.001	

Use of univariate analysis with adjusted confounding factors such as sex, age, the location of the lesions, the primary lesion area, and the type of the lesions: *Significant level of intergroup comparison, **Significance level obtained from within the group comparison

DISCUSSION

The main treatment for leishmaniasis is the use of chemical medicines that have many complications. Antimonial compounds are used as medicine for treating this disease and have been the mainstay of treatment for leishmaniasis; however, the treatment failure is on the rise in many areas.^[7] Other drugs such as amphotericin B, ketoconazole, allopurinol, paromomycin, and metronidazole, which are mostly used in

combination, are also used in this regard.^[7] One of the major recent trends in medical care is the growth of complementary therapies, the most significant of which is the current use of herbs in the prevention and treatment of chronic diseases. Herbal medicines are more acceptable than chemical medicines due to their naturalness, different therapeutic effects, less complications, and cost-effectiveness.^[19,20]

In patients with cutaneous leishmaniasis, the most important goal is treatment. For treating skin lesions, it is better to use therapies that have less systemic absorption and fewer complications. Therefore, considering that the combination of *P. ovata* and vinegar has been mentioned as lesion relief in TPM texts,^[17,18] the very aim of the present study was to examine the topical effect of the combination of *P. ovata* and vinegar in the improvement of the rural cutaneous leishmaniasis lesions.

The results of this study revealed that in the 1st week after using the combination of *P. ovata* and vinegar, the lesion area increased slightly and the lesion was associated with an ejection. However, the lesion area was still not significantly different between the case and control groups. Moreover, the lesion area in the case group, similar to the control group, also had a decreasing trend in the 2nd, 3rd, and 4th weeks. However, the effectiveness of the combination of *P. ovata* and vinegar

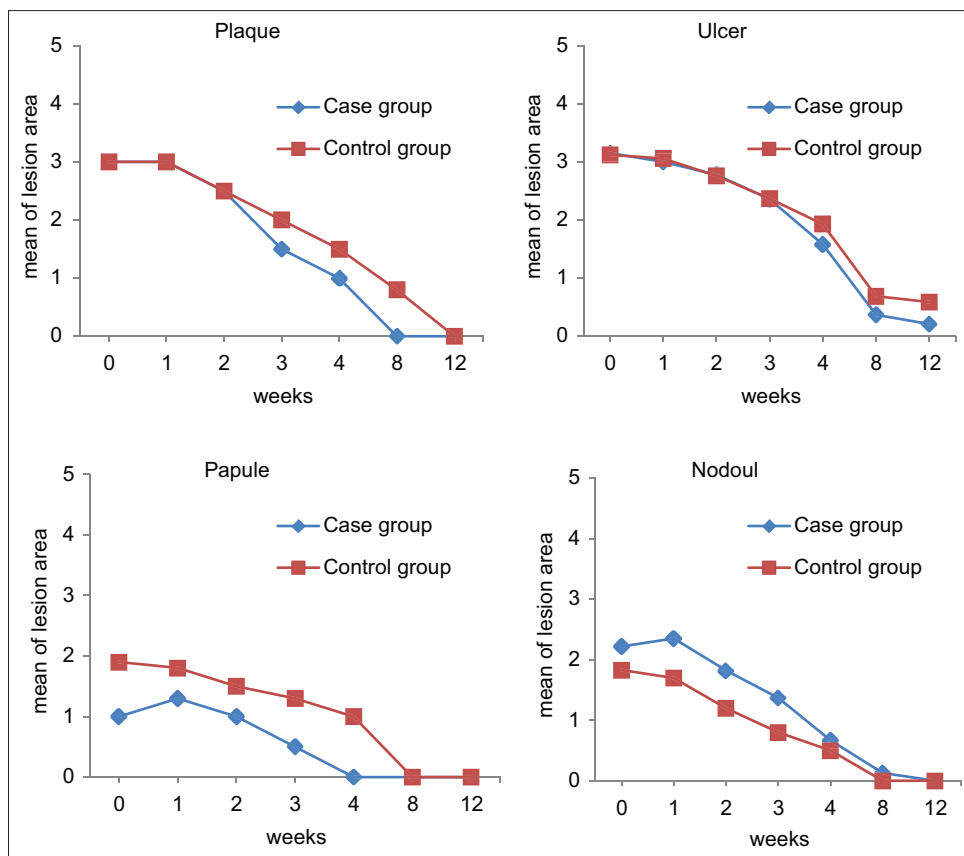


Figure 2: The two groups' lesion area considering the lesion type over 12 weeks

Table 3: Frequency distribution of lesion improvement in the two groups

Improvement of the cutaneous leishmaniasis lesion	Case group (%)	Control group (%)	P
Complete improvement	39 (88.7)	29 (65.9)	0.019
Fourth/eighth/twelfth weeks	5/17/15	0/25/4	
Partial improvement	3 (6.8)	15 (34.1)	
Nonimprovement	2 (4.5)	0	

Complete improvement: 100% improvement till the 12 weeks,
 Partial improvement: 50%-99% improvement till the 12 weeks,
 Nonimprovement: <50% improvement till the 12 weeks

became more apparent in the 8th and 12th weeks such that the lesion area in the case group was significantly less than that of the control group over the mentioned weeks. In fact, the successful outcome of treatment (complete improvement) after 12 weeks of follow-up in the case group with 88.7% was significantly higher than that of the control group with 65.9%.

In this regard, according to previous studies, topical washing of the lesion with vinegar or the topical combination of vinegar and Armenian flowers can be used to dry the lesion and remove non-living tissue until it reaches healthy tissue. By doing so, the dry lesion and dead tissues are peeled off and removed. Even the use of this compound as an ointment on the lesion is recommended to remove dead tissue and achieve healthy tissue.^[17]

In line with the present study, only one study has been conducted by Moshfe *et al.*, the results of which showed that the effect of vinegar and glucantime on the improvement of cutaneous leishmaniasis lesion in Balb/c mice was not significant and in contrast, *P. ovata* alone had the least effect. In addition, the combination of vinegar and *P. ovata* had a significant effect on the improvement of these lesions. They have noted that the main effect of the treatment was related to vinegar and *P. ovata* played a supporting role.^[18]

Consequently, it can be stated that vinegar can be considered as a strong disinfectant that can be used for cleaning and disinfecting. Vinegar can treat pimples, acne, pain, and inflammation caused by lesions. Although irritation occurs in the topical applications of vinegar, it is a good sign indicating that vinegar disinfectant compounds are actively fighting against bacteria or viruses and destroying dead lesion tissue.^[21,22]

In addition, there is a report on the use of chopped *P. ovata* leaves to improve poisoning.^[23] It is also used to relieve itching and inflammation of the skin and is used as a dressing to heal herpes, lesions, and abscess. Traditionally, it can also be helpful for sting and gout. Leaf extracts also indicated lesion healing activity in rabbits (due to chlorogenic acid and neochlorogenic acid).^[24]

Aqueous extract of the leaves also has an antimicrobial activity due to its aglycone. The aerial parts of this plant have an anti-inflammatory and diuretic property.^[25,26] The flower extract of the plant has reduced the arterial blood pressure in dogs.^[27]

Many other previous studies have evaluated a wide variety of herbal remedies such as the antioxidant effects of lemon, *Cinnamomum camphora* (L.) J. Presl, and *Crocus sativus* L., the anti-bacterial effects of lemon, *Juniperus excelsa* M. Bieb, and *Vitriolum (ferrous sulfate)*, the anti-inflammatory and antiseptic properties of honey, lemon, *Commiphora myrrha* (Nees) Engl., *Cuminum cyminum* L., *Aristolochia* sp., and *Boswellia* sp., the antipruritic effect of topical *camphor* on leishmaniasis lesion, the antimicrobial effect of *olibanum* and *cumin*, and the anti-promastigote effect of mountain tea, *M. germanica* leaves, and *calendula officinalis* on leishmaniasis.^[28-38]

Another important finding of this study was the higher effectiveness of the combination of vinegar and *P. ovata* on the improvement of Ulcer, Plaque, and Papule types of the lesion in the case group as compared with the control group in the 4th and 8th weeks; however, an adverse effect was observed with respect to the Nodule type. In fact, it seems that the current intervention cannot have a positive and acceptable effect on the Nodule lesion and it may be necessary to avoid its use for this type of lesion.

As it was already mentioned, although various studies have been conducted addressing the effects of various herbal plants, it is significant to mention two points. First, no study has addressed the effect of various medicinal plants as an ointment on various lesions of leishmaniasis, and there is little research on the effectiveness of the combination of vinegar and *P. ovata* on leishmaniasis. Therefore, the present study seems to be innovative in this respect. However, the failure to evaluate lesion parasitic load, the shorter follow-up, and the small sample size can be considered as limitations of the present study. Therefore, it seems that further studies with a larger sample size and with a focus on different types of leishmaniasis lesions are required to achieve more accurate and reliable results for generalizing the findings to the community.

CONCLUSION

According to the results of the present study, the mean leishmaniasis lesion area in the case group that received the topical application of the combination of *P. ovata* and vinegar was significantly less than that of the control group (glucantime injection alone) in the eighth and twelfth weeks. After 12 weeks, the complete improvement of the lesion in the case group was much more than that of the control group.

Financial support and sponsorship

Nil.

Conflicts of interest

There are no conflicts of interest.

REFERENCES

- John DT, Petri WA. Markell & Voge's Medical Parasitology. 10th Sea ed. Singapore: Elsevier Pte Limited; 2020.
- Jorjani O, Mirkarimi K, Charkazi A, Shahamat YD, Mehrbakhsh Z, Bagheri A. The epidemiology of cutaneous leishmaniasis in Golestan Province, Iran: A cross-sectional study of 8-years. Parasite Epidemiol Control 2019;5:e00099.
- Alemayehu B, Alemayehu M. Leishmaniasis: A review on parasite, vector and reservoir host. Health Sci J 2017;11:1.
- Aronson NE, Joya CA. Cutaneous leishmaniasis: Updates in diagnosis and management. Infect Dis Clin North Am 2019;33:101-17.
- Jaffary F, Nilforoushzadeh MA, Ansari N, Rahimi M. Treatment of cutaneous leishmaniasis: *Cassia fistula* fruit gelintralesionalglucantime vs. placebo gel – Intralesionalglucantime combination. Tehran Univ Med J 2010;67:705-11.
- Pirooz B, Moradi G, Alinia C, Mohamadi P, Gouya MM, Nabavi M, et al. Incidence, burden, and trend of cutaneous leishmaniasis over four decades in Iran. Iran J Public Health 2019;48 Suppl 1:28-35.
- Blum J, Desjeux P, Schwartz E, Beck B, Hatz C. Treatment of cutaneous leishmaniasis among travellers. J Antimicrob Chemother 2004;53:158-66.
- Reithinger R, Dujardin JC, Louzir H, Pirmez C, Alexander B, Brooker S. Cutaneous leishmaniasis. Lancet Infect Dis 2007;7:581-96.
- Firooz A, Khatami A, Khamesipour A, Nassiri-Kashani M, Behnia F, Nilforoushzadeh M, et al. Intralesional injection of 2% zinc sulfate solution in the treatment of acute old world cutaneous leishmaniasis: A randomized, double-blind, controlled clinical trial. J Drugs Dermatol 2005;4:73-9.
- Farajzadeh S, Heshmatkhan A, Vares B, Mohebbi E, Mohebbi A, Aflatoonian M, et al. Topical terbinafine in the treatment of cutaneous leishmaniasis: Triple blind randomized clinical trial. J Parasit Dis 2016;40:1159-64.
- Vecchiato NL. Traditional medicine. In: The Ecology of Health and Disease in Ethiopia. Philadelphia: Routledge; 2019: 157-78.
- Parvizi MM, Zare F, Handjani F, Nimrouzi M, Zarshenas MM. Overview of herbal and traditional remedies in the treatment of cutaneous leishmaniasis based on traditional Persian medicine. Dermatol Ther 2020;33:e13566.
- Nazem Jahan M. Exir-e Azam. Tehran (Iran): Medicine Science University of Iran. 2008. p. 452.
- Rahmani, Arshad H. *Cassia fistula* Linn: Potential candidate in the health management. *Pharmacognosy research*, 2015;7:217.
- Asmar M, Farahmand BM, Aghighi Z, Ghaemi N, Ayat EA. *In vitro* and *in vivo* evaluation of therapeutic effects of vinca major alkaloids on leishmania major. Journal of school of public health and institute of public health research; 2002;1:1-8.
- Hejazi SH, Shirani-Bidabadi L, Zolfaghari-Baghbaderani A, Saberi SE, Nilforoushzadeh MA, Moradi SH, et al. Comparison effectiveness of extracts of thyme, yarrow, henna and garlic on cutaneous leishmaniasis caused by *L. major* in animal model (Balb/c). J Med Plants 2009;8:129-60.
- Mozafari O, Yousef Pour M, Mozafari A, Soufizadeh A, Yousefi SS. Cutaneous leishmaniasis from the perspective of traditional Iranian medicine. J Mazandaran Univ Med Sci 2016;26:277-84.
- Moshfe A, Bahmani M, Naghmachi M, Askarian SH, Rezaei A, Zare RH. Antileishmanial effect of plantago psyllium and white vinegar on *Leishmania major* lesion in balb/c mice. In: National Symposium and 1st International Congress of Parasitology and Parasitic Diseases in Iran. Shiraz; 2012. p. 136-7.
- Saghafipour A, Mozaffari E, Rezaei F. The evaluation of intralesional glucantime and cryotherapy plus intralesional glucantime therapeutic efficacy on zoonotic cutaneous leishmaniasis: A randomized clinical trial. Int J Pediatr 2017;5:6689-97.
- Ghazanfari T, Shahrokhi S, Naseri M, Jalali Nadoushan MR, Yaraie R, Kardar M. The cytotoxic effects of ACA1 on human melanoma cell line. J Mazandaran Univ Med Sci 2006;16:42-9.
- Borda LJ, Macquhae FE, Kirsner RS. Wound dressings: A comprehensive review. Curr Dermatol Rep 2016;5:287-97.
- Elhage KG, St. Claire K, Daveluy S. Acetic acid and the skin: A review of vinegar in dermatology. Int J Dermatol 2021;60:1-8.

23. Basiri S, Shekarforoush SS, Mazkour S, Modabber P, Kordshouli FZ. Evaluating the potential of mucilaginous seed of psyllium (*Plantago ovata*) as a new lead biosorbent. *Bioact Carbohydr Diet Fibre* 2020;24:100242.
24. Sarfraz RM, Khan H, Maheen S, Afzal S, Akram MR, Mahmood A, *et al.* *Plantago ovata*: A comprehensive review on cultivation, biochemical, pharmaceutical and pharmacological aspects. *Acta Pol Pharm* 2017;74:739-46.
25. Haddadian K, Haddadian K, Zahmatkash M. A Review of *Plantago* Plant. *Indian Journal of Traditional Knowledge*, 2014; 13: 681-685.
26. Reddy PR, Vandana KV, Prakash S. Antibacterial and anti-inflammatory properties of *Plantago ovata* Forssk. leaves and seeds against periodontal pathogens: An *in vitro* study. *Ayu* 2018;39:226-9.
27. Dermarderosian A. The Review of Natural Productions. Facts and Comparison. Vol. 13. United States: Wolters Kluwer Company USA; 2001. p. 473-6.
28. Parvizi MM, Handjani F, Moein M, Hatam G, Nimrouzi M, Hassanzadeh J, *et al.* Efficacy of cryotherapy plus topical *Juniperus excelsa* M. Bieb cream versus cryotherapy plus placebo in the treatment of old world cutaneous leishmaniasis: A triple-blind randomized controlled clinical trial. *PLoS Negl Trop Dis* 2017;11:e0005957.
29. Nilforoushzadeh MA, Jaffary F, Moradi S, Derakhshan R, Haftbaradaran E. Effect of topical honey application along with intralesional injection of glucantime in the treatment of cutaneous leishmaniasis. *BMC Complement Altern Med* 2007;7:13.
30. Hamdan II, Afifi FU. Studies on the *in vitro* and *in vivo* hypoglycemic activities of some medicinal plants used in treatment of diabetes in Jordanian traditional medicine. *J Ethnopharmacol* 2004;93:117-21.
31. Marongiu B, Piras A, Porcedda S, Scorciapino A. Chemical composition of the essential oil and supercritical CO₂ extract of *Commiphora myrrha* (Nees) Engl. and of *Acorus calamus* L. *J Agric Food Chem* 2005;53:7939-43.
32. Morteza-Semnani K, Saeedi M. Constituents of the essential oil of *Commiphora myrrha* (Nees) Engl. var. molmol. *J Essent Oil Res* 2003;15:50-1.
33. Das I, Chakrabarty RN, Das S. Saffron can prevent chemically induced skin carcinogenesis in Swiss albino mice. *Asian Pac J Cancer Prev* 2004;5:70-6.
34. Lee HJ, Hyun EA, Yoon WJ, Kim BH, Rhee MH, Kang HK, *et al.* *In vitro* anti-inflammatory and anti-oxidative effects of *Cinnamomum camphora* extracts. *J Ethnopharmacol* 2006;103:208-16.
35. Nejad AS, Bahmani M, Shah NA, Shah SA, Rafeian-Kopaei M. Beliefs of herbal therapies of the community of the Ilam city of Ilam province, Iran. *J Pharm Pharmacogn Res* 2018;6:299-317.
36. da Silva ET, de Andrade GF, Araújo AD, Almeida AD, Coimbra ES, de Souza MV. *In vitro* assessment of camphor hydrazone derivatives as an agent against *Leishmania amazonensis*. *Acta Parasitol* 2020;65:203-7.
37. Nilforoushzadeh MA, Hejazi SH, Zarkoob H, Shirani-Bidabadi L, Jaffary F. Efficacy of adding topical honey-based hydroalcoholic extract *Nigella sativa* 60% compared to honey alone in patients with cutaneous leishmaniasis receiving intralesional glucantime. *J Skin Leishmaniasis* 2010;1:1-7.
38. Chevrier MR, Ryan AE, Lee DY, Zhongze M, Wu-Yan Z, Via CS. *Boswellia carterii* extract inhibits TH1 cytokines and promotes TH2 cytokines *in vitro*. *Clin Diagn Lab Immunol* 2005;12:575-80.