

## Severe main bronchus obstruction due to pulmonary schwannoma: A Case Report

Ahmad Shirinzadeh<sup>1</sup>, Reza Ershadi<sup>1</sup>, Abdolhamid Amouei<sup>2,\*</sup>, Jamal Jafari<sup>1</sup>, Hamidreza Soltani<sup>1</sup>, Shadi Kargar<sup>1</sup>, Fariba Binesh<sup>3</sup>

1. Department of General Surgery, Shahid Sadoughi University of medical sciences and health services, Yazd, Iran

2. Department of Pediatric Surgery, Shahid Sadoughi University of medical sciences and health services, Yazd, Iran

3. Department of Pathology, Shahid Sadoughi University of medical sciences and health services, Yazd, Iran

\*Corresponding author: Dr. Abdolhamid Amouei, Department of Pediatric Surgery, Shahid Sadoughi University of medical sciences and health services, Yazd, Iran. E-mail: amooehamid@gmail.com. ORCID ID: 0000-0002-0508-0957

Received: 26 October 2019

Accepted: 05 January 2022

### Abstract

Pulmonary schwannoma is a rare neoplasm that arises from peripheral nerve sheath, Schwann cells, in the lungs and mostly remains asymptomatic for months. This report presents a seven-year-old female patient with an occasional cough and fever. She was hospitalized due to the lack of response to outpatient treatments, including antibiotics and antifebrile. A biopsy was taken from the mass by bronchoscopy, and the pathology report indicated the presence of a low-grade spindle cell, Verocay body, and Antoni B areas. Based on the pathologic findings, immunohistochemical (IHC) analysis was requested. The results indicated diffusely positive for S-100 protein, and accordingly, the diagnosis of schwannoma was confirmed. Thoracotomy and lobectomy were performed. Tracheobronchial schwannoma can be treated with surgical resection or bronchoscopy.

**Key words:** Bronchus, Pulmonary schwannoma, Obstruction

### Introduction

With progress in the treatment of pediatric Pulmonary schwannoma is a rare neoplasm that arises from peripheral nerve sheath, Schwann cells, in the lungs (1) and mostly remains asymptomatic for months. Life-threatening conditions are infrequent in this type of malignancy (2). Till now, limited studies are available related to the presentation of tracheal schwannoma. Its treatment is also controversial as surgical resection or endoscopic excision are accepted as the treatment of choice (3, 4). The current report aimed to present a patient with obstruction of right hemi-lung due to overgrowth of a pulmonary schwannoma in her right main bronchus.

### Case Report

The patient was a seven-year-old female with an occasional cough and fever. She was hospitalized due to the lack of

response to outpatient treatments including antibiotics and antifebrile. The patient had continuous fever with dry coughs. There was no other complaint during this period; however, she had lost about 1.5 kg weight in the last three months. In the systemic examination, the patient had an axillary temperature of 38.30C with a respiratory rate of 16 breaths per minute and reduced respiratory sounds with some scattered rhonchi in the inferior lobe of the right lung. The rest of the examinations had normal conditions since normal results were obtained from the rest of the tests. Lung collapse was observed in the inferior lobe of the right lung (Figure 1). Due to prolonged fever, a bronchoscopy was performed after administering the antibiotic. An intraluminal mass was observed in the proximal bronchus intermedius (Figure.2). The mass completely blocked the bronchus, which had a regular and smooth margin. A

biopsy was taken from the mass, and the pathology report indicated the presence of a low-grade spindle cell, Verocay body, and Antoni B areas. Based on the pathologic findings, immunohistochemical (IHC) analysis was requested, and the results indicated diffusely positive for S-100 protein (Figure.3), and accordingly, the diagnosis of schwannoma was confirmed. Furthermore, thoracic computed tomography (CT) scan was requested for further examinations. The intraluminal mass, bronchus intermedius, interlobar lymphadenopathy, and inferior lobe collapse were observed. Since schwannoma occurred over the distal region with a size of 1.5 x 1.2 cm, and severe adhesion to the lateral anterior and posterior bronchus intermedius was observed, the patient underwent right posterolateral thoracotomy and inferior lobectomy (Figure.4). In addition, middle lobectomy was also performed due to the severity of adhesion and the proximal bronchus intermedius involvement. The patient was discharged after seven days with good general health, and no evidence of recurrence was observed in the bronchoscopy in the three-month follow-up.

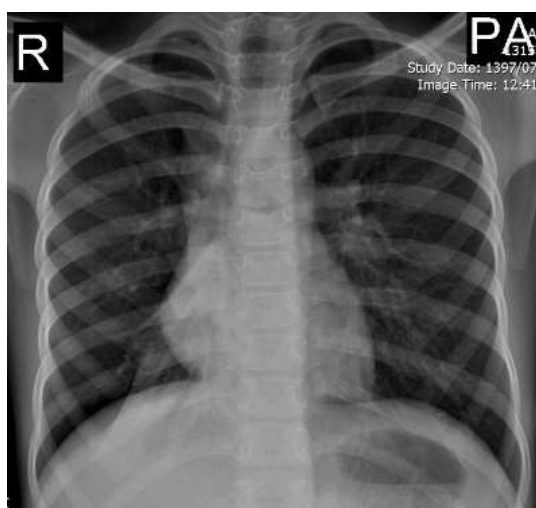


Figure.1. Chest X-rays demonstrating collapse of inferior lobe of the right lung.

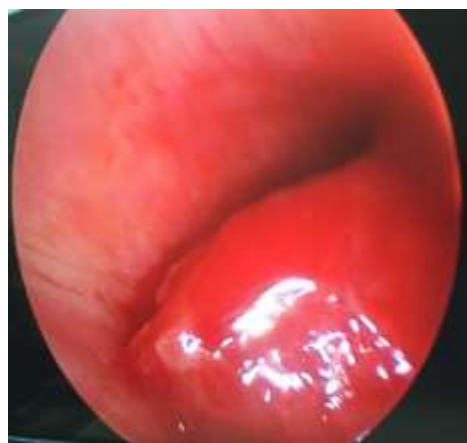

Figure.2. An intraluminal mass was observed in the proximal bronchus intermedius in Bronchoscopy.

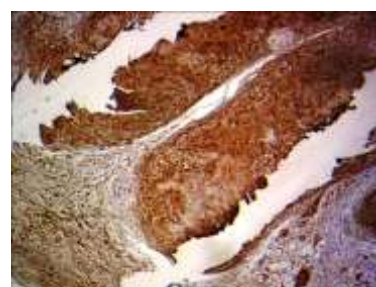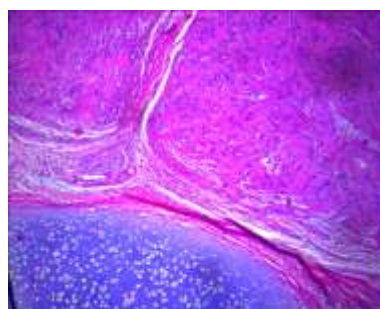


Figure 3. Pathology report indicated the presence of a low-grade spindle cell, Antoni A and B areas, and diffusely positive for S-100 protein.

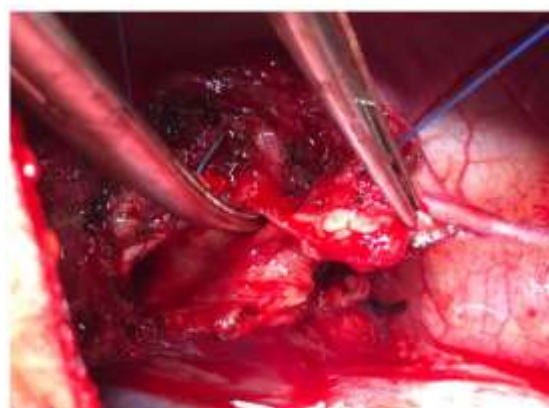


Figure.4. Middle lobe lobectomy was done due to intermedium bronchus involvement.

## Discussion

Endobronchial schwannoma is a benign and rare tumor, accounting for about 2% of the benign endobronchial tumors (5). The clinical manifestations of this disease are quite diverse and heavily depend on the location of the tumor and the size and level of the bronchial obstruction (6). Symptoms include dry coughs or sputum, fever, hemoptysis, dyspnea, and pneumonia (2). The non-specificity of the symptoms of schwannoma complicates its diagnosis. This patient underwent bronchoscopy since a definitive diagnosis of early tracheobronchial schwannoma is usually obtained by bronchoscopy and a tissue biopsy (5). Biopsy was performed due to the resistance of the fever and lobar pneumonia to treatments.

Additionally, a multi-slice CT scan was employed to examine the extraluminal tumor's spread, site, and size. In addition, we used an optical microscope, and we found that the tumor is composed of specific structural cells, including cellular areas of Antoni A, structural areas of Antoni A and B, and Verocay bodies (7). The results obtained from schwannoma and neurofibroma were diffusely positive for S-100 protein using the immunostaining technique.

## Conclusion

Tracheobronchial schwannoma can be treated with surgical resection or bronchoscopy. The probability of recurrence is higher in the bronchoscopy than in the surgery; however, the overall prognosis is highly desirable for the patients undergoing either surgery or bronchoscopy. It is noteworthy that at least one year of follow-up is recommended to monitor the probable recurrence.

## Acknowledgement

Authors wish to thank the staff of the Surgery Ward of Shahid Sadoughi Hospital in Yazd, Iran and Mmes. Salari and Azar Abyar for their kind assistance

with managing the patient and gathering data.

## References

1. Moon H, Park SJ, Kim SR, Park HS, Lee YC. Benign intercostal schwannoma mimicking a solitary metastasis from lung cancer. *Thorax* 2010; 65(8):753-4.
2. Uchiyama M, Shimoyama Y, Usami N, Ito S, Yasuda A, Kawaguchi K, et al. Primary pulmonary malignant schwannoma with extension to the tracheal carina. *J Thorac Cardiovasc Surg* 2007; 133(1):265-267.
3. Tang LF, Chen ZM, Zou CC. Primary intratracheal neurilemmoma in children: case report and literature review. *Pediatr Pulmonol* 2005; 40:550-553.
4. Righini CA, Lequeux T, Laverriere MH. Primary tracheal schwannoma: one case report and a literature review. *Eur Arch Otorhinolaryngol* 2005; 262:157-160.
5. Westphal FL, Lima LC, Lima-Netto JC, Tavares Mde A, Gil Fde S. Lung cancer and schwannoma--the pitfalls of positron emission tomography. *J Bras Pneumol* 2014; 40(3):319-321.
6. Kamiyoshihara M, Igai H, Ohsawa F, Yoshikawa R, Yazawa T. Schwannoma arising in a lymph node mimicking metastatic pulmonary carcinoma. *Respir Med Case Rep* 2018; 25:18-21.
7. Elstner K, Granger E, Wilson S, Kumaradevan N, Chew M, Harris C. Schwannoma of the pulmonary artery. *Heart Lung Circ* 2013; 22(3):231-213.
8. Laursen BB, Frandsen JL, Knudsen TE. Intrapulmonary schwannoma presenting as a primary lung cancer. *Ugeskr Laeger* 2014; 176(27):V01140047-01140050.
9. Diaz Beveridge R, Richart Aznar P, Nunez Lozano C, Chirivella Casanova M, Corbellas Aparicio M, Montalar Salcedo J. Orbital and myocardial metastases of a primary pulmonary melanotic schwannoma. *Clin Transl Oncol* 2010; 12(7):509-511.
10. Petteruti F, De Luca G, Lerro A, Luciano A, Cozzolino I, Pepino P.

Intercostal ancient schwannoma mimicking an apical lung tumour. *Thorax* 2008; 63(9):845-846.

11. Tang GC, Piao YS, Zhao L, Lu DH. Lung adenocarcinoma metastasizing to cerebellopontine angle schwannoma (collision tumor). *Acta Neurochir* 2007; 149(1):87-90

12. Fujikawa T, Shiono S, Abiko M, Kanauchi N, Uchino H, Kim C, et al. [Pulmonary schwannoma with hypervascularity; report of a case]. *Kyobu Geka* 2008; 61(12):1075-1077.

13. Rodriguez CA, Munhoz AH, Zampier JA, Silva AP, Fustes OH. [Benign intercostal nerve schwannoma simulating pulmonary neoplasm: case report]. *Arq Neuropsiquiatr* 2004; 62(4):1100-3.

14. Tsukada H, Osada H, Kojima K, Yamate N. Bronchial wall schwannoma removed by sleeve resection of the right stem bronchus without lung resection. *J Cardiovasc Surg (Torino)* 1998; 39(4):511-3.

*Table I: Review of the literature*

Reference	Year	Gender/ Age	Country	Location	Clinical presentation	Outcome
1 Kamiyoshihara et al <sup>6</sup>	2018	Male / 72	Japan	Right lower lobe	Dyspnea, cough	Right lower lobectomy
2 Elstner et al <sup>7</sup>	2013	Male/ 65	Australia	Lateral wall of the left pulmonary artery	Dyspnea on exertion	Completely resected
3 Laursen et al <sup>8</sup>	2014	Female/ 61	Denmark	Right upper lobe	Non-response to antibiotic pneumonia	Right upper lobectomy
4 Diaz Beveridge et al <sup>9</sup>	2010	Male/60	Italy	Pulmonary peripheral nerves near the midline	Dyspnea and chest pain	Radical surgery
5 Petteruti et al <sup>10</sup>	2008	Female/ 56	Italy	Intercostal	Chest pain and cough	Complete excision
6 Tang et al <sup>11</sup>	2007	Female/ 57	China	Superior lobe of the left lung	Not symptomatic During metastasis workup	Medical treatment
7 Fujikawa et al <sup>12</sup>	2008	Female/ 54	Japan	Lower lobe of the right lung	Mass shadow in the right pulmonary hilum	Segmentectomy
8 Rodriguez <sup>13</sup>	2004	Male/37	Brazil	Left Hemithorax	Dry cough and pain	Completely resected
9 Tsukada <sup>14</sup>	1998	Male / 28	Japan	Bronchial wall	Dyspnea	Resected en-bloc with the stem bronchi without pulmonary resection