

Available online at www.sciencedirect.com

ScienceDirect

journal homepage: www.elsevier.com/locate/radcr

Case Report

Incidental diagnosis of a rare endobronchial schwannoma in a 7-year-old girl: A case report [☆]

Mehdi Ghaderian Jahromi, MD^{a,b}, Abdolrahim Sadeghi Yakhdani, MD^c,
Mahdi Saeedi-Moghadam, Ph.D^{b,*}, Pooya Iranpour, Ph.D^{a,b}

^aDepartment of Radiology, Shiraz University of Medical Sciences, Shiraz, Iran

^bMedical Imaging Research Center, Shiraz University of Medical Sciences, Shiraz, Iran

^cDepartment of Radiology, Shahid Sadoughi University of Medical Sciences, Yazd, Iran

ARTICLE INFO

Article history:

Received 20 June 2022

Revised 27 July 2022

Accepted 31 July 2022

Keywords:

Case report

Schwannomas

Endobronchial

ABSTRACT

Schwannomas are nerve sheath tumors that arise from Schwann cells and are mainly benign. The likelihood of endobronchial schwannoma amongst all intrapulmonary tumors is up to 0.2% and mainly presents late. This study described a pediatric endobronchial schwannomas case discovered incidentally during rigid bronchoscopy. This case is uncommon, and its report can help physicians diagnose the same cases. The case was a 7-year-old girl presenting with fever and cough who had no history of pulmonary disease or relevant family history. Physical examination, chest radiography, CT scan, and bronchoscopy were performed on the patient. A biopsy was taken from the observed mass obstructing the bronchus during bronchoscopy. The mass was resected. Pathology revealed low-grade spindle cell neoplasm and confirmed schwannoma in immunohistochemistry. Endobronchial schwannomas can happen in children presenting with simple symptoms. For benign lesions, the prognosis is generally good. Due to the slow growth of these tumors and the potential for recurrence after resection, long-term follow-up may be needed.

© 2022 Published by Elsevier Inc. on behalf of University of Washington.

This is an open access article under the CC BY-NC-ND license (<http://creativecommons.org/licenses/by-nc-nd/4.0/>)

Introduction

Primary neurogenic tumors arising from the trachea and bronchus are rare and often present late. Schwannomas are benign nerve sheath tumors that stem from Schwann cells. Although it is a rare condition, endobronchial schwannomas have been previously reported in the literature [1]. The chance

of initial neurogenic lung tumors is as low as 0%-2% of all lung tumors [2]. The clinical symptoms are variable, including bronchial obstruction, hemoptysis [3], and lung collapse [4]. This study described pediatric endobronchial schwannomas presenting with fever and cough, discovered incidentally during rigid bronchoscopy. This case is uncommon, and its report can help physicians diagnose the same cases.

[☆] Competing Interests: None.

* Corresponding author.

E-mail address: m_saeedimoghadam@yahoo.com (M. Saeedi-Moghadam).

<https://doi.org/10.1016/j.radcr.2022.07.115>

1930-0433/© 2022 Published by Elsevier Inc. on behalf of University of Washington. This is an open access article under the CC BY-NC-ND license (<http://creativecommons.org/licenses/by-nc-nd/4.0/>)

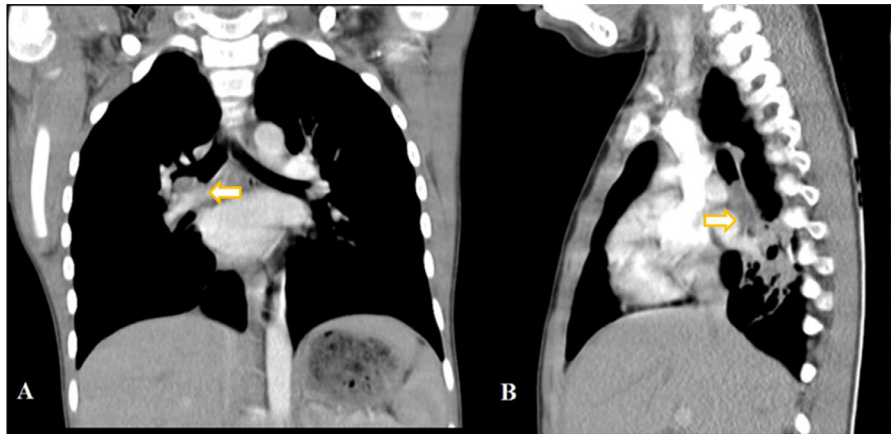

Fig. 1 – Chest CT scan. (A) Coronal view shows a mass lesion in the right bronchus. (B) Sagittal view also shows the mass and associated atelectasis. Arrows are shown the intrabronchial mass.

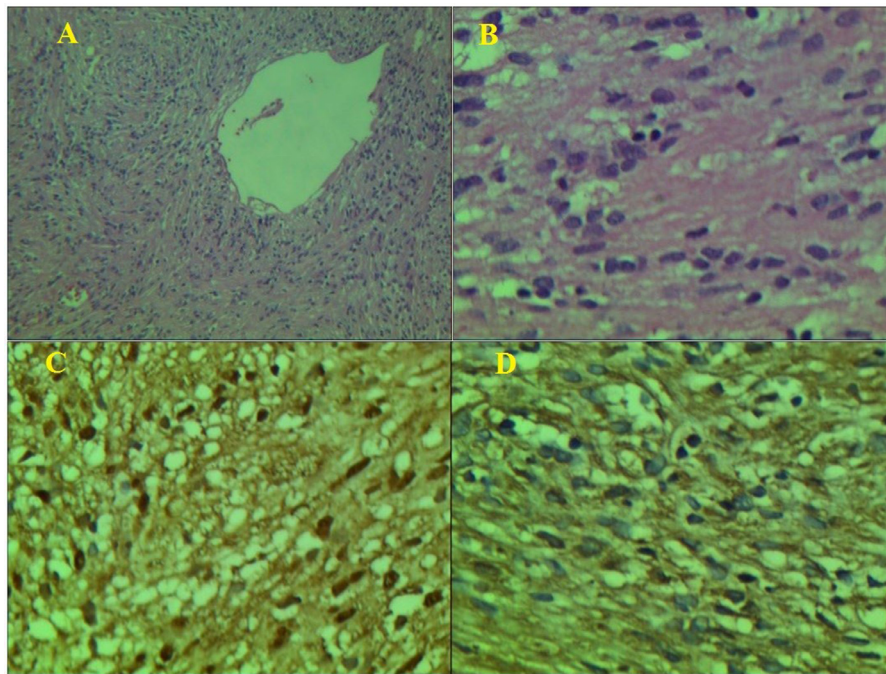


Fig. 2 – Staining of different proteins. (A) *100 H&E staining. (B) *400 H&E staining. (C) *400 S-100 staining. (D) *400 VIM staining.

Case report

A 7-year-old girl was referred to a University-affiliated hospital with a fever and dry cough history last month. During this period, she was repeatedly treated with antibiotics for right lung pneumonia. There was no history of pulmonary disease or relevant family history. On physical examination, the pulmonary sound of the lower zone of the right lung was not audible. The chest X-ray (CXR) showed an opacity in the right para-cardiac with no silhouette sign (Fig. 1). Contrast computerized tomography (CT) showed an 18 × 10 mm mass in the right-side bronchus intermedius, which collapsed the api-

cal and medial segments of the right lower lobe. Rigid bronchoscopy was performed, and a biopsy was taken from the mass obstructing the bronchus. Finally, the mentioned mass was resected by rigid bronchoscopy, and open surgery was not performed for the patient. Pathology revealed low-grade spindle cell neoplasm and confirmed schwannoma in immunohistochemistry.

On macroscopic evaluation, the intrabronchial mass in the right bronchus was well-circumscribed, vegetative, and pink. The microscopic examination revealed a tumoral tissue composed of oval to spindle-shaped cells with minimal nucleus pleomorphism and inconspicuous mitotic activity in a whorl pattern with foci of cystic degeneration and the presence of a

few verocay bodies. In immunohistochemistry, S-100 and VIMENTIN (VIM) are diffusely stained (Fig. 2).

Discussion

Schwannomas or Neurilemmomas are benign tumors that mainly stem from medullated nerves. The spinal nerve roots are known as the central location of these tumors [5]. Endobronchial tumors are not prevalent, and considering the rare nature of Schwannomas, endobronchial schwannoma is highly infrequent, with the chance of 0.2% of all neoplasms that might occur intrapulmonary [6]. The whole part of the tracheobronchial tree can be the point of Schwannomas occurrence [1].

Schwannomas are rarely associated with von Recklinghausen neurofibromatosis and rarely undergo malignant transformation [7]. Endobronchial schwannoma's location, size, and extent of obstruction are essential factors in clinical manifestation; therefore, the symptoms might also vary [4]. CXR might be normal or unremarkable, requiring more detailed imaging [7]. To determine the mass size and its relationship to adjacent tissue, CT and MRI scans can help [7]. If there are suspicious airway lesions, bronchoscopy is necessary and trustful. Typically evaluation by flexible fiberoptic bronchoscopy is more preferred than rigid bronchoscopy, but the latter has been reported [8]. Histologically, schwannoma spindle cells are structured in a highly cellular and palisading nuclei pattern (Antoni A) or a less cellular and more fibrous pattern (Antoni B) [8].

The strength of this case report was that endobronchial schwannomas were almost always reported in adults [3,9–11]; however, this study presents a 7-year-old child and suggests considering this clinical situation in diagnosis. The limitation of this study was that there was no information about the patient's follow-up.

Endobronchial schwannomas can happen in children with simple symptoms such as cough and fever. For benign lesions, the prognosis is generally good. Due to the slow growth of these tumors and the potential for recurrence after resection, long-term follow-up may be needed [7].

Patient consent

The authors have obtained a written informed consent from the patient to publish his case (including publication of images).

REFERENCES

- [1] Kasahara K, Fukuoka K, Konishi M, Hamada K, Maeda K, Mlkasa K, et al. Two cases of endobronchial neurilemmoma and review of the literature in Japan. *Intern Med* 2003;42(12):1215–18.
- [2] Roviato G, Montorsi M, Varoli F, Binda R, Cecchetto A. Primary pulmonary tumours of neurogenic origin. *Thorax* 1983;38(12):942–5.
- [3] Stouffer CW, Allan RW, Shillingford MS, Klodell CT. Endobronchial schwannoma presenting with bronchial obstruction. *Interact Cardiovasc Thorac Surg* 2010;10(1):133–4.
- [4] Oxner CR, Shinnors MJ, Godin DA, Lyn IT, Brent RB, McFadden PM. Obstructing tracheobronchial schwannoma. *J La State Med Soc* 2005;157(3):159.
- [5] Harkin J, Reed R. Atlas of tumor pathology: tumors of the peripheral nervous system, second series, fascicle 3. Washington, DC: Armed Forces Institute of Pathology; 1969.
- [6] Nasiri H, Zeki AA, Albertson TE. A rare diagnosis: Endobronchial schwannoma. *J Respir Dis* 2010;38(2):1–5.
- [7] Righini CA, Lequeux T, Laverrierre M-H, Reyt E. Primary tracheal schwannoma: one case report and a literature review. *Eur Arch Otorhinolaryngol Head Neck* 2005;262(2):157–60.
- [8] Weiner DJ, Weatherly RA, DiPietro MA, Sanders GM. Tracheal schwannoma presenting as status asthmaticus in a sixteen-year-old boy: airway considerations and removal with the CO2 laser. *Pediatr Pulmonol* 1998;25(6):393–7.
- [9] Dumoulin E, Gui X, Stather DR, MacEachern P, Tremblay A. Endobronchial schwannoma. *J Bronchol Interv Pulmonol* 2012;19(1):75–7.
- [10] Onal M, Ernam D, Atikcan S, Memiş L. Endobronchial schwannoma with massive hemoptysis. *Tuberk Toraks* 2009;57(1):89–92.
- [11] Imen T, Sadok BM, Raoudha A, Ksissa S, Yosra B, Yosr BA, et al. Endobronchial schwannoma in adult: a case report. *Respir Med Case Rep* 2021;33:101396.