

## An uncommon case of brucellosis with ocular presentation

Um caso incomum de brucelose com apresentação ocular

Zahra Farzinvas<sup>1</sup> , Mohammad Mahdi Raji<sup>2</sup> , Masoudreza Manaviat<sup>2</sup> <sup>1</sup> Tehran University of Medical Sciences and Health Services, Tehran, Iran.<sup>2</sup> Shahid Sadoughi University of Medical Sciences and Health Services, Yazd, Iran.

## How to cite:

Farzinvas Z, Raji MM, Manaviat M. An uncommon case of brucellosis with ocular presentation. Rev Bras Oftalmol. 2022;81:e0028.

## doi:

<https://doi.org/10.37039/1982.8551.20220028>

## Keywords:

Brucellosis; Ocular brucellosis;  
Eye diseases; Headache;  
Papilledema; Doxycycline;  
Rifampin; Ceftriaxone

## Descritores:

Brucelose; Brucelose ocular;  
Oftalmopatias; Cefaleia;  
Papiledema; Doxiciclina;  
Rifampicina

## Received on:

Nov 23, 2021

## Accepted on:

Feb 2, 2022

## Corresponding author:

Zahra Farzinvas  
Farabi Eye Hospital  
Tehran, Iran  
Email: zahra1142000@yahoo.com

## Institution:

Shahid Sadoughi University of Medical  
Sciences and Health Services, Yazd, Iran.

## Conflict of interest:

no conflict of interest.

## Financial support:

the authors received no financial support  
for this work.



Copyright ©2022

## ABSTRACT

We report an unusual case of brucellosis presented with headache, diminished vision, papillitis and multiple peripapillary hemorrhages accompanied by subretinal fluid extending up to macula. Diagnosis of brucellosis was made based on positive polymerase chain reaction of cerebrospinal fluid sample for *Brucella* species DNA, accompanied by a raised titer of anti-brucella antibodies. Patient showed remarkable improvement on triple drug therapy in form of doxycycline, rifampicin and ceftriaxone.

## RESUMO

Relatamos um caso incomum de brucelose apresentada com cefaleia, visão diminuída, papilite e múltiplas hemorragias peripapilares acompanhadas por fluido sub-retinal, estendendo-se até a mácula. O diagnóstico de brucelose foi feito com base na reação em cadeia da polimerase positiva de amostra de líquido cefalorraquidiano para DNA de espécies de *Brucella*, acompanhada por um título elevado de anticorpos antibrucela. O paciente apresentou melhora notável com a terapia tripla com drogas na forma de doxiciclina, rifampicina e ceftriaxona.

## INTRODUCTION

Brucellosis (Malta fever) is the most common zoonosis disease that affects people at any age group. Despite the reduction in the prevalence of brucellosis, it still remains an important health problem in endemic areas such as the Middle East, Mediterranean and South America.

*Brucella* is an intracellular Gram-negative aerobic coccobacilli that is transmitted by consumption of uncooked meat or unpasteurized dairy products, especially involving reticuloendothelial cells.<sup>(1)</sup>

Ocular involvement is a rare but serious complication of brucellosis. It can appear during the active phase of disease or later.<sup>(2)</sup>

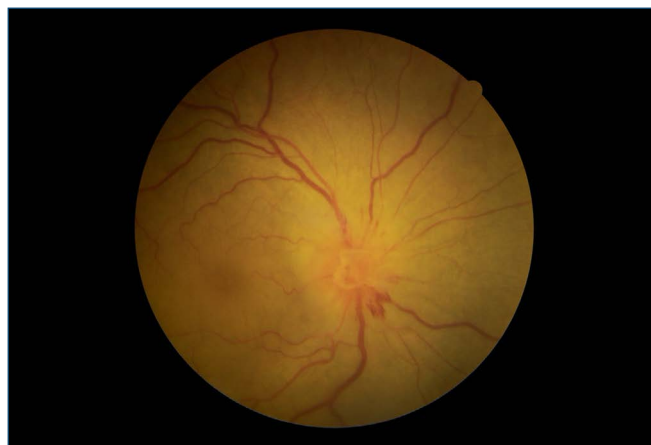Ophthalmic signs are unusual and include red eye, ocular pain, and diminished visual acuity due to optic neuritis, retinal vasculitis and preretinal hemorrhage.<sup>(3)</sup>

We hereby report a patient with bilateral optic neuropathy secondary to brucellosis.

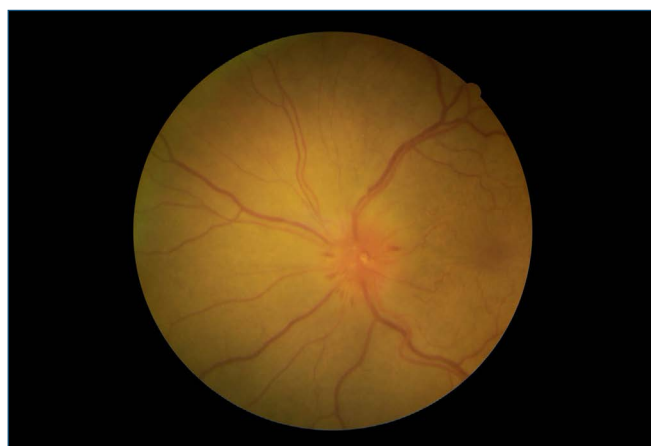## CASE REPORT

A 66 year-old female patient presented to the ophthalmology clinic of the Shahid Sadoughi Hospital (Yazd, Iran) with a chief complaint of decreased vision in both eyes with onset one week before, associated with severe headache. Best corrected visual acuity (BCVA) in the right eye was counting finger (CF) at 50cm and in the left eye was CF at 1m. Ocular motility was in full range and painless. Pupillary reflexes were considerably reduced in both eyes. Anterior segment examination revealed no abnormality, except for early cataract in both eyes. Intraocular pressure (IOP) was in normal range in both eyes. Posterior segment examination revealed optic nerve head swelling and hyperemia with blurred margins (papillitis), and multiple peripapillary flame-shaped hemorrhages (Figures 1 and 2), accompanied by subretinal fluid extending up to macula in both eyes in optical coherence tomography imaging of macula (Figures 3 and 4).

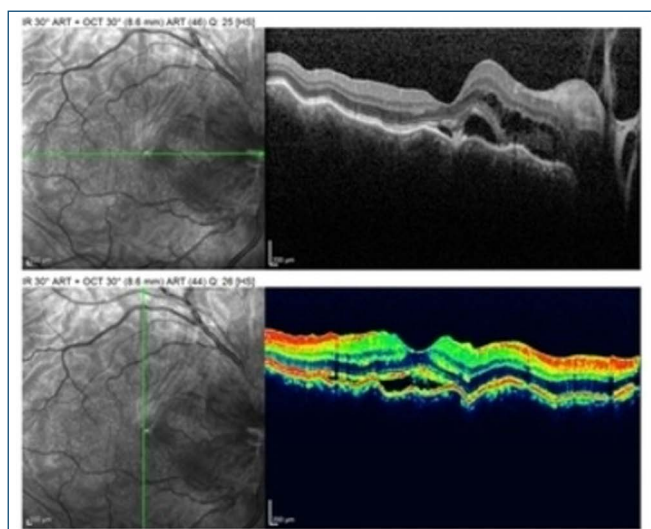
Fluorescein angiography showed vascular leakage and staining of vessels and hyperfluorescence of the optic disc in both eyes (Figure 5 and 6). The patient underwent brain magnetic resonance imaging, which was normal. Hematology test showed leukocytosis (10,700WBCs). Because of severe headache and diminished vision, the patient underwent lumbar puncture (LP) test. The cerebrospinal fluid (CSF) analysis revealed clear fluid, intracranial pressure (ICP) of 17cmH<sub>2</sub>O, and glucose of 58mg/dL, LDH of 40IU/L, and 320 WBCs with 90% of lymphocytes. Polymerase chain reaction (PCR) of CSF sample for *Brucella* species DNA was strongly positive. ELISA test



**Figure 1.** Fundus photography of the right eye.



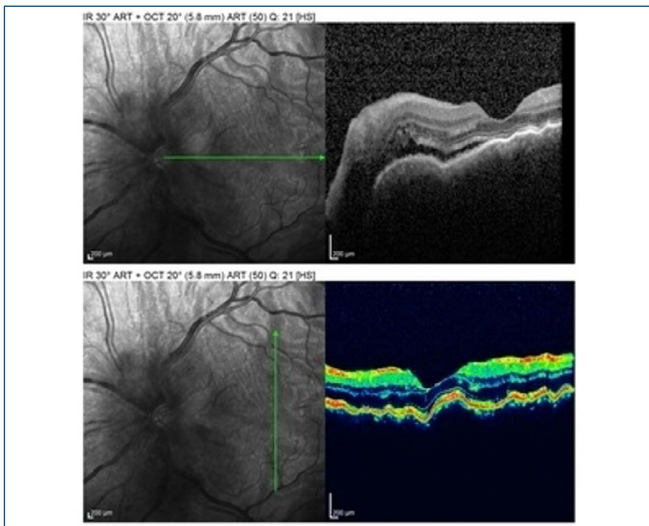
**Figure 2.** Fundus photography of the left eye.



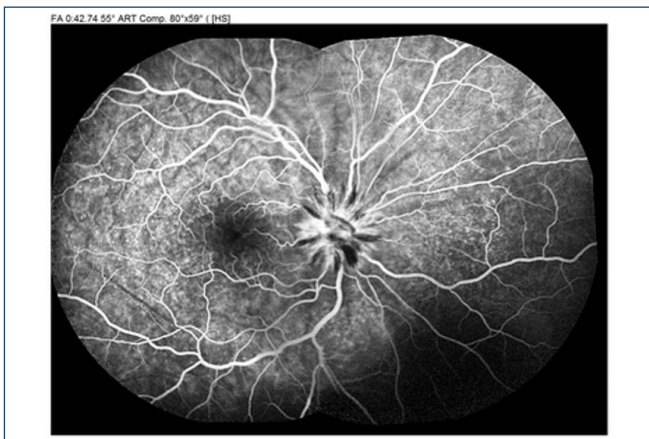
**Figure 3.** Optical coherence tomography of the right eye.

for anti-toxoplasmosis antibody titer and PPD tests were negative.

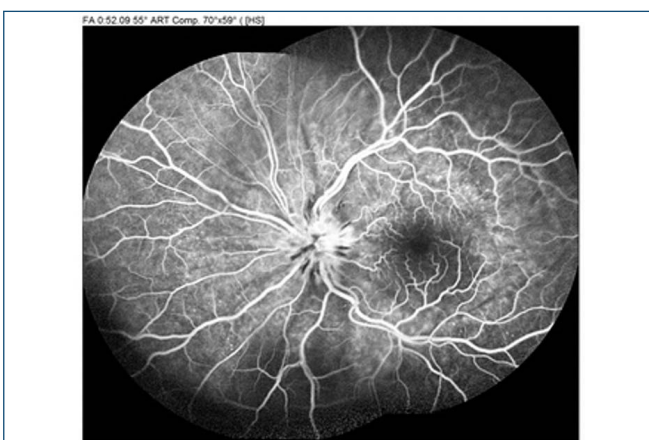
Patient was hospitalized with diagnosis of brucellosis and treated with systemic antibiotics of ceftriaxone 2g intravenous BID, rifampin 300mg TDS and doxycycline 100mg



**Figure 4.** Optical coherence tomography of the left eye.



**Figure 5.** FA-right eye.



**Figure 6.** FA-left eye.

BID for 1 month. After 1 month of systemic antibiotic therapy, the Wright tube test, Coombs Wright, and 2-mercaptoethanol (2ME) test became negative. After 1 month of treatment, LP was repeated, and the CSF analysis revealed decrease in leukocytes (79WBCs): also, PCR test of CSF sample for

*Brucella* species DNA became negative. Peripapillary hemorrhages and subretinal fluid were completely absorbed, and optic nerve head congestion decreased after treatment. The visual acuity of patient was improved to 20/400 in the right eye and 20/200 in the left eye.

After discharge, the patient was asked for authorization to use her illness data for academic purposes and she signed an informed consent.

## DISCUSSION

Brucellosis is an infectious disease that may affect any parts of the body. The four species that are pathogenic for humans are *Brucella melitensis*, *Brucella abortus*, *Brucella suis*, and *Brucella canis*. Hosts are usually cows, camels, sheep and goats. *Brucella melitensis* is the most common and virulent species.

Brucellosis is a chronic granulomatous disease with systemic presentations, including back pain, headache, fatigue, fever, loss of appetite, muscular pain, perspiration, weight loss, arthralgia, cough, neural signs, abdominal pain, diarrhea, and constipation. Serum agglutination, ELISA and blood culture are used to confirm the diagnosis of brucellosis.<sup>(4)</sup>

Recently, Guven et al. diagnosed neurobrucellosis because of the presence of one of the following criteria: symptoms and signs suspect of neurobrucellosis, isolation of *Brucella* species from CSF and/or presence of anti-*Brucella* antibodies in the CSF, presence of lymphocytosis, increased protein, and decreased glucose levels in the CSF, or findings in magnetic resonance imaging or computed tomography.<sup>(5)</sup>

Cerebrospinal fluid culture, when positive, is considered the gold standard in laboratory diagnosis of neurobrucellosis. However, serological approaches are the mainstay in the diagnosis of neurobrucellosis due to the relatively lower efficacy of bacterial culture.<sup>(6)</sup>

Although ocular involvement is uncommon in brucellosis and mostly observed in patients with chronic brucellosis, any ocular structure may be involved, including keratitis, uveitis, choroiditis, episcleritis, endophthalmitis, dacryoadenitis, and optic neuropathy.<sup>(7)</sup> Optic nerve involvement, including optic neuritis and papilledema, has been described in about 10% of patients with ocular brucellosis.<sup>(8,9)</sup> It seems that optic neuropathy in brucellosis is secondary to meningeal inflammation (neurobrucellosis) and subsequent axonal degeneration. Ischemic, vasculitic, and immune-mediated mechanisms have also been suggested.

The visual prognosis of brucella-related optic neuropathy is usually good after an appropriate course of

antibiotic and steroid therapy. However, severe cases with permanent visual impairment have been described.<sup>(10)</sup>

In 2005, Lashay reported a young female case of brucellosis with severe visual loss, diplopia, bilateral optic nerve swelling, subhyaloid hemorrhage, and retinal vasculitis. Clinical and ocular findings, except for optic disc atrophy, improved within 3 months after anti-brucella treatment.<sup>(3)</sup>

In summary, brucellosis may cause various systemic and ocular complications, including vasculitis, optic neuritis and retinal hemorrhage. There are no specific diagnostic features that may suggest ocular involvement caused by brucellosis. Therefore, ocular brucellosis must always be considered in endemic areas. A detailed ocular examination, including fundoscopy, should be performed in all patients with a diagnosis of systemic brucellosis, particularly in endemic areas. This could minimize the risk of blindness associated with brucellosis.

## REFERENCES

1. Doganay M, Aygen B. Human brucellosis: an overview. *Int J Infect Dis.* 2003;7:173-82.
2. Shakir RA. Neurobrucellosis. *Postgrad Med J.* 1986;62(734):1077-9.
3. Lashay AR, Manaviat MR, Azimi R, Riazi M. Case presentation: optic neuritis, preretinal hemorrhage, and retinal vasculitis as ocular manifestations of brucellosis. *Annals of Ophthalmology.* 2005;37(4):291-3.
4. Sauret J, Villissova N. Human brucellosis. *J Am Board Fam Pract* 2002;15(5):401-6.
5. Guven T, Ugurlu K, Ergonul O, Celikbas AK, Gok SE, Comoglu S, et al. Neurobrucellosis: clinical and diagnostic features. *Clin Infect Dis.* 2013;56(10):1407-12.
6. Araj GF. Update on laboratory diagnosis of human brucellosis. *Int J Antimicrob Agents.* 2010;36 Suppl 1:S12-7.
7. Gungör K, Bekir NA, Namiduru M. Ocular complications associated with brucellosis in an endemic area. *Eur J Ophthalmol.* 2002;12(3):232-7.
8. Rolando I, Olarte L, Vilchez G, Lluncor M, Otero L, Paris M, et al. Ocular manifestations associated with brucellosis: a 26-year experience in Peru. *Clin Infect Dis.* 2008;46(9):1338-45.
9. Sungur GK, Hazirolan D, Gurbuz Y, Unlu N, Duran S, Duman S. Ocular involvement in brucellosis. *Can J Ophthalmol.* 2009;44(5):598-601.
10. Tunc M, Durukan H. Bilateral severe visual loss in brucellosis. *Ocul Immunol Inflamm.* 2004;12(3):233-6.