



# Doxepin accelerates the healing process of burn wounds in mice

Elham Saberzadeh<sup>1</sup>, Mohsen Zabihi<sup>2\*</sup>, Ehsan Motaghi<sup>3</sup>,  
Fatemeh Shishehbor<sup>4</sup>

<sup>1</sup>School of Pharmacy, Shahid Sadoughi University of Medical Sciences, Yazd, Iran, <sup>2</sup>Department of Pharmacology, School of Pharmacy, Shahid Sadoughi University of Medical Sciences, Yazd, Iran, <sup>3</sup>Department of Physiology and Pharmacology, School of Medicine, Kurdistan University of Medical Sciences, Sanandaj, Iran, <sup>4</sup>Department of Pathology, Shahid Sadoughi University of Medical Sciences, Yazd, Iran

## Corresponding Author:

Mohsen Zabihi,  
Department of Pharmacology,  
School of Pharmacy, Shahid  
Sadoughi University of  
Medical Sciences, Yazd, Iran.  
Tel: +983538243419-20.  
E-mail: mzabihi@ssu.ac.ir

**Received:** Nov 23, 2019

**Accepted:** Aug 23, 2020

**Published:** Feb 17, 2021

## ABSTRACT

Wound healing following a skin burn is still a concern due to poor effectiveness and the side effects of the available topical and systemic drugs. Doxepin hydrochloride is an approved antidepressant drug (Application No.: 022036) which is effective for the treatment of moderate pruritus in patients with eczema and atopic dermatitis. The current study has evaluated the effect of topical and systemic doxepin to improve the histopathologic process of second-degree burn wound in mice. The mice were divided into six groups ( $n = 6$ ), including topical normal saline group, topical glycerin group, positive control group (topical phenytoin), topical doxepin 5% group, and two concentration of doxepin injection groups, including 15 and 30 mg/kg. An experimental burn wound was induced by contacting a heated rod 2 cm in diameter with the dorsal skin of animals for 3 s. Care was taken twice daily for 21 days. Then, the mice were euthanized and the skin samples were used for histopathologic evaluations. A significant difference was observed on polymorphonuclear leukocytes (PMNs), collagen formation, epithelialization, and angiogenesis among the experimental groups compared to the control group ( $P < 0.05$ ). Injection of doxepin (15 mg/kg) and topical glycerin significantly increased epidermis thickness compared to the other groups ( $P < 0.05$ ). These results suggested that topical and systemic doxepin is effective in the wound healing process.

**Keywords:** Doxepin, mice, second-degree burn, wound healing

## INTRODUCTION

Burn injury is a destructive injury which related to tissue damage, skin inflammation, and local or systemic infection.<sup>[1]</sup> Silver sulfadiazine 1% cream with antibacterial activity is an important treatment for burn wounds.<sup>[2]</sup> Silver sulfadiazine 1% cream causes the side effects, including neutropenia, erythema multiforme, crystalluria, and methemoglobinemia<sup>[3]</sup> and delays wound healing. It is cautioned that silver sulfadiazine 1% cream should not be used for a long time on extended wounds.<sup>[4]</sup> Itching is the most common complication in a burn which takes several weeks to heal. increasing mast cell population and histamine release in a chronically pruritic burn wound can be an etiologic factor for some of these complications.<sup>[5]</sup> Histamine also increases surface wound blood flow, which would explain the raised red surface.<sup>[6]</sup>

Doxepin, a tricyclic antidepressant, is a very potent H1 and H2 histamine receptor blocker.<sup>[7]</sup> Doxepin cream uses to control the pruritus of atopic dermatitis, eczema, urticaria, and other skin disorders.<sup>[8]</sup> Recently, Kwa *et al.* (2019) compared doxepin cream and oral antihistamines for the treatment of itch in burn patients: A multi-center triple-blind randomized controlled trial revealed that the effectiveness of doxepin cream was similar to oral antihistamines in reducing itch. Plasma levels of topical doxepin are usually non-detectable or 25 times less detectable than the levels needed for its central nervous system effect.<sup>[7]</sup> Doxepin cream alters the wound healing process, possibly by decreasing mast cell numbers or stimulus it to release histamine. The main side effect of doxepin, like other antihistamines, is mild transient drowsiness in about 10% of patients. There is not any correlation between its somnolence and the anti-itch activity.<sup>[7]</sup>

Despite the researches have done for evaluation of the effect of doxepin for the healing of itch, there is a lack of information about its systemic and topical application on burn-induced wound healing. In addition, systemic doxepin attenuates inflammation and accelerates healing in some mucosal inflammatory conditions such as ulcerative colitis.<sup>[9,10]</sup> Hence, the current study evaluates the effect of systemic and topical doxepin to improve the histopathologic process of second-degree burn wound in mice.

## MATERIALS AND METHODS

### Animals

Sixty male NMRI mice (25–30 g) were purchased from the laboratory animal house of Shahid Sadoughi University of Medical Sciences, Yazd, Iran. The mice were housed individually in temperature and humidity-controlled room ( $21 \pm 2^\circ\text{C}$ , 55–60%) with a 12 h light-dark cycle and free access to standard food and tap water. The animals were kept and handled according to the local guidelines of care and work with laboratory animals in Yazd University of Medical Sciences (IR.SSU.MEDICINE.REC.1398.056). All experimental procedures were carried according to the Guide for the Care and Use of Laboratory Animals to Investigate Experimental Pain in Animals.<sup>[11]</sup>

### Study Protocol

Back hair of the mice was shaved, and burn was induced under general anesthesia following i.p. injection of ketamine (50 mg/kg) and xylazine (10 mg/kg).

An experimental second-degree burn wound was induced by contacting a heated rod (2 cm<sup>2</sup>) on the dorsal skin of the animal for 3 s at 100°, according to a pilot study (Figure 1). The mice were divided into six groups ( $n = 6$ ), including two control groups (topical normal saline and topical glycerin), positive control group (topical phenytoin 1%), topical doxepin 5% (in glycerin base as 5% w/w), and two groups of systemic doxepin as i.p. injection (15 mg/kg and 30 mg/kg).

The animals were kept separately in the cages. The topical treatments were applied twice daily and the systemic doxepin was injected daily. The duration of the treatments was considered 21 days (Figure 2). We did not use any bandage on the wound. The mice were sacrificed with diethyl ether in a desiccator after 21 days since the starting of the treatment and the samples of the whole burned skin were removed from the body and kept in formalin 10% solution. The assessment of wound healing was done according to histological evaluations of the collected tissues.

### Histological Evaluations

The tissue was fixed in Bouin's solution (7.5 mL saturated picric acid, 2.65 mL glacial acetic acid, and 2.5 mL 7% formaldehyde), post-fixed in 70% alcohol, and embedded in paraffin blocks. A full-thickness tissue section was obtained, deparaffinized, and stained with hematoxylin-eosin. The different histological parameters of skin tissue were scored under an optical microscope double blindly.

The histological parameters, including polymorphonuclear migration (PMNs, Scores:  $\text{PMN} \geq 40$ : 0,  $10 \leq \text{PMN} < 40$ : 1,  $\text{PMN} < 10$ : 2), collagen formation, epithelialization, and angiogenesis scores, were evaluated. Finally, the total score was calculated. The total score is a summation of the other scores, including PMN migration, collagen formation, epithelialization, and angiogenesis scores.

### Statistical Analysis

Data are expressed as mean  $\pm$  S.E.M, which were analyzed by one-way ANOVA followed by Tukey's *post hoc* test. All statistical analyses were made using SPSS software (version 19).

## RESULTS

There was not any significant variation in animal's weight during the study. Their behaviors since the second day of burn induction were normal in all of the groups.

The appearance of histological parameters is shown in Figure 3.

A significant decrease was observed on PMNs among experimental groups compared to the control saline group ( $P < 0.05$ ). However, there was no significant difference ( $P > 0.05$ ) between doxepin and glycerin groups compared to the phenytoin group (Figure 4).

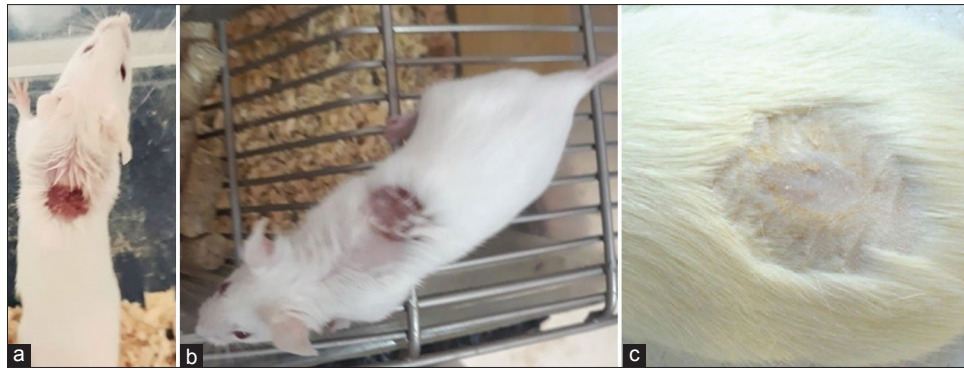
A significant difference was observed on collagen formation among experimental groups compared to the control saline group ( $P < 0.05$ ). However, there was no significant difference ( $P > 0.05$ ) between doxepin and phenytoin-treated groups compared to the glycerin group (Figure 5).

Effect of the topical and systemic doxepin on angiogenesis in the experimental burn-induced wound in mice is presented in Figure 6. A significant difference was observed on angiogenesis among experimental groups in comparison to the control saline groups ( $P < 0.05$ ). However, there was no significant difference between doxepin and phenytoin-treated groups compared to the glycerin group ( $P > 0.05$ ).

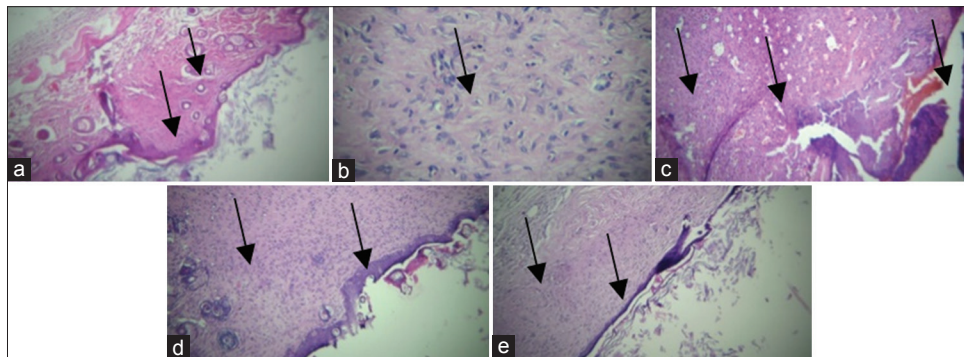
Injection of doxepin (15 mg/kg) and topical glycerin significantly ( $P < 0.05$ ) increased epidermis thickness compared to the other groups [Figure 7].



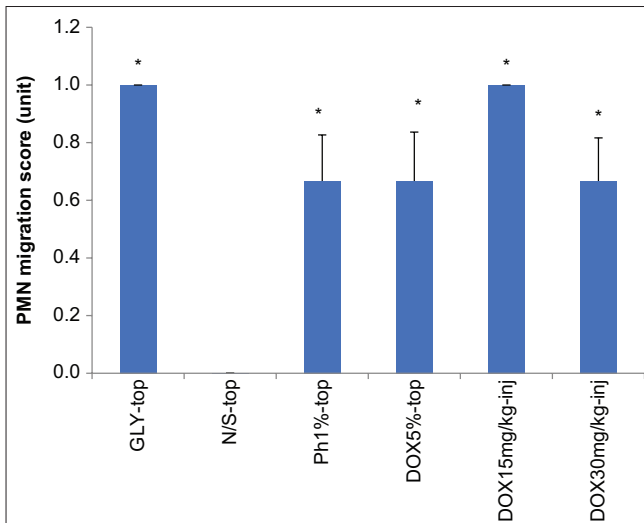
**Figure 1:** Experimental burn induction



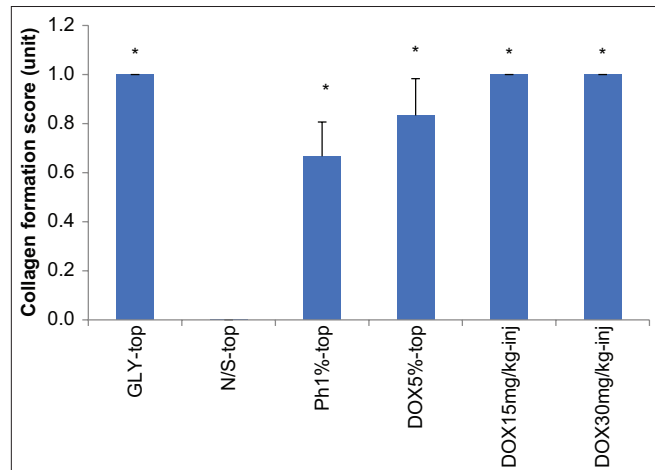
**Figure 2:** The appearance of wounds caused by second-degree burns in the studied animals. (a) The 1<sup>st</sup> day after induction of burns, (b) 21 days after induction of burns in the animals treated with normal saline, (c) 21 days after induction of burns in the animals treated with doxepin (15 mg/kg, i.p.)



**Figure 3:** Histopathological presentation of mice second-degree burned skin in treatment groups after 21 days treatment. (a) The appearance of a skin sample in systemic doxepin (i.p. injection, 15mg/kg), mild angiogenesis, thick epidermis, and small number of PMNs. (b) Topical doxepin 5% and mild angiogenesis. (c) Topical normal saline, severe angiogenesis, without epidermis, and large number of PMNs. (d) Topical glycerin, mild angiogenesis, thick epidermis, and small number of PMNs. (e) Topical phenytoin and thin epithelium.



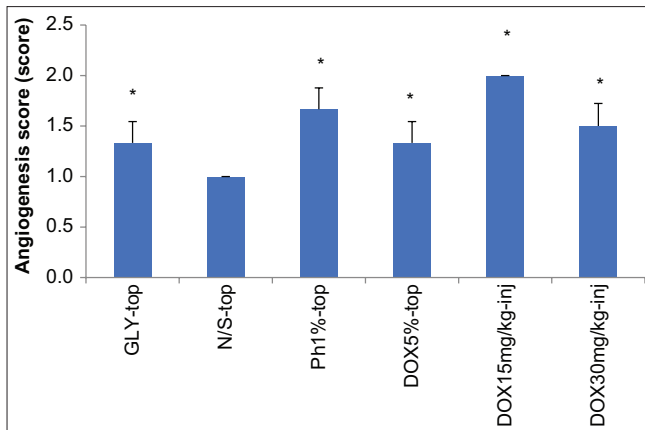
**Figure 4:** Effect of the topical and systemic doxepin on polymorphonuclear leukocytes (PMNs) in experimental burn-induced wound in mice. GLY-top, topical glycerin; N/S-top, topical normal saline; Ph1%-top, phenytoin cream 1%; and Dox, doxepin. Data are analyzed as mean  $\pm$  S.E.M, ( $n = 6$ ). \* $P < 0.05$ , in comparison with N/S-top group, # $P < 0.05$ , in comparison with GLY-top group, one-way ANOVA followed by Tukey's *post hoc* test



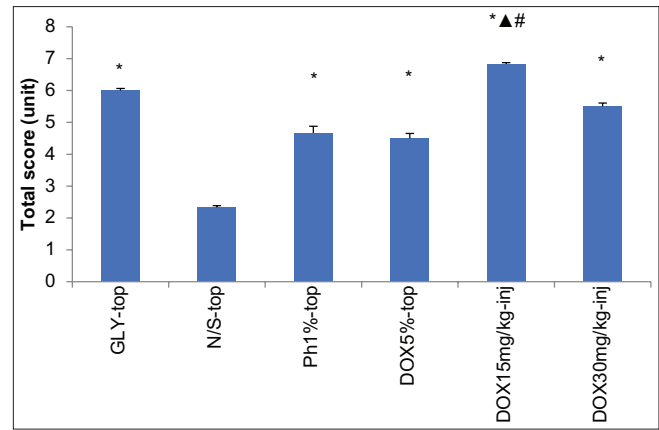
**Figure 5:** Effect of the topical and systemic doxepin on collagen formation in experimental burn-induced wound in mice. GLY-top, topical glycerin; N/S-top, topical normal saline; Ph1%-top, phenytoin cream 1%; and Dox, doxepin. Data are analyzed as mean  $\pm$  S.E.M, ( $n = 6$ ). \* $P < 0.05$ , in comparison with N/S-top group, # $P < 0.05$ , in comparison with GLY-top group, one-way ANOVA followed by Tukey's *post hoc* test

The total histopathological score improved in experimental groups compared to the control saline group ( $P < 0.05$ ).

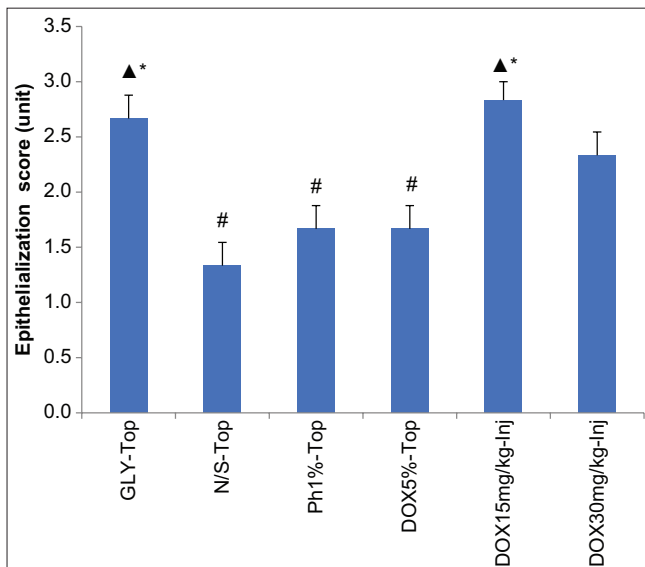
However, there was no significant difference ( $P < 0.05$ ) between doxepin and phenytoin-treated groups compared to the glycerin group [Figure 8].



**Figure 6:** Effect of the topical and systemic doxepin on angiogenesis in experimental burn-induced wound in mice. GLY-top, topical glycerin; N/S-top, topical normal saline; Ph1%-top, phenytoin cream 1%; and Dox, doxepin. Data are analyzed as mean  $\pm$  S.E.M, ( $n = 6$ ). \* $P < 0.05$ , in comparison with N/S-top group, # $P < 0.05$ , in comparison with GLY-top group, one-way ANOVA followed by Tukey's *post hoc* test



**Figure 8:** Effect of the topical and systemic doxepin on the histopathological score in the experimental burn-induced wound in mice. GLY-top, topical glycerin; N/S-top, topical normal saline; Ph1%-top, phenytoin cream 1%; and Dox, doxepin. Data are analyzed as mean  $\pm$  S.E.M, ( $n = 6$ ). \* $P < 0.05$ , in comparison with N/S-top group, # $P < 0.05$ , in comparison with GLY-top group,  $P < 0.05$ , in comparison with Ph1%-top, one-way ANOVA followed by Tukey's *post hoc* test



**Figure 7:** Effect of the topical and systemic doxepin on epidermis thickness in experimental burn-induced wound in mice. GLY-top, topical glycerin; N/S-top, topical normal saline; Ph1%-top, phenytoin cream 1%; and Dox, doxepin. Data are analyzed as mean  $\pm$  S.E.M, ( $n = 6$ ). \* $P < 0.05$ , in comparison with N/S-top group, # $P < 0.05$ , in comparison with GLY-top group, one-way ANOVA followed by Tukey's *post hoc* test

## DISCUSSION

Burn injuries are related to infections, scars, and disabilities which lead to psychosocial and economic problems.<sup>[12]</sup> Resuscitation of patients with fluid and antibiotics for prevention of dehydration and infections, respectively, is the mainstay of therapy prior to the regeneration of the damaged tissues and skin.<sup>[13]</sup> Although some medications and herbal products have been used for wound healing and tissue regeneration, there is not any suitable and high effective treatment for healing the burn wound and its morbidities. In the previous studies, it has figured out that antidepressants can inhibit

inflammatory disorders.<sup>[14,15]</sup> *In vitro* studies have shown that doxepin reduces stimulated release of inflammatory and pro-inflammatory cytokines including, IL-1 $\beta$ , IL6, and TNF- $\alpha$  in some inflammatory conditions.<sup>[9,10]</sup> In this study, it reduced inflammation in the skin injuries induced by the experimental burn and improved wound healing.

Doxepin is a tricyclic antidepressant which inhibits the reuptake of serotonin and norepinephrine, exerts a very low inhibition of dopamine reuptake,<sup>[16]</sup> and was approved by the FDA in 2010.<sup>[17]</sup> Doxepin is a selective histamine antagonist and binds to H1 and H2 receptors, in which function is accountable for the drug's sleep-promoting properties.<sup>[17]</sup> It also effects on serotonin, muscarinic cholinergic receptors, and adrenergic receptors and it has anti-inflammatory effects in some conditions such as ulcerative colitis by reduction of inflammatory cytokines.<sup>[9,10]</sup> Doxepin is going to become a promising contestant for inflammatory and pain conditions in patients with depressive disorders.<sup>[18]</sup> Recently, Kwa *et al.* (2019) studied comparing doxepin cream to oral antihistamines for the treatment of itch in burn patients: A multi-center triple-blind randomized controlled trial revealed the effectiveness of the doxepin cream. Its effects were similar to oral antihistamines in reducing itch. Doxepin cream reduces the itch scores more than oral antihistamines.<sup>[7]</sup> The difference in neuropeptide expression and extent of nerve damage in deeper burn wounds is the main factors which lead to pruritic stimuli differences in superficial burn wounds.<sup>[19]</sup> Due to involvement of another mechanisms other than histamine release in the late proliferative/remodeling phase, antihistamines are not effective in late phase of wound injury,<sup>[20]</sup> explaining doxepin improves wound injury through the mechanisms other than its antihistaminic effects.

Tissue repair is a synchronized and magnificently coordinated interplay of several cellular and biochemical components, including homeostasis, inflammation, proliferation, and tissue remodeling.<sup>[21]</sup> To explore the underlying mechanism of burn wound healing, histopathological changes of the burn wound

healing process were also evaluated. The epidermis then continued to increase the thickness and eventually projected into the dermis. However, the healing process of the dermis is much more complicated. Adipose cells are the most abundant cells observed in the wound on the 3<sup>rd</sup> day after-burn. Following the healing of the wound, the number of adipose cells gradually decreases and totally disappeared. The role of adipose cells in wound healing is still ambiguous. Inflammatory cells are the first cells that entered into the wound. They appeared in the wound area to scavenge bacteria and other foreign particles to avoid wound infection.<sup>[22]</sup> Notably, doxepin is currently available as a cream for the symptomatic treatment of pruritus. The results of a novel study comparing the pain reducing effect of a topical preparation containing 3.3% doxepin alone or a topical preparation containing 3.3% doxepin combined with 0.075% capsaicin to placebo in patients with a variety of chronic neuropathic pain problems indicated that each treatment provides similar pain-reducing effects and both are superior to placebo.<sup>[23]</sup> Doxepin can attenuate the pain in a burn injury through its local anesthetic and anti-inflammatory effects.

In this study, all the treatment groups studied were treated within 21 days of the onset of the burn. Improving the histopathological parameters compared to control in this particular period can be the reason for accelerating the healing process of wounds.

In conclusion, the results show that the effect of topical doxepin is not significantly different from that of topical glycerin and its effects can be attributed to its glycerin base, but systemic doxepin can accelerate the healing process of burn wounds.

Doxepin formulations can promise to use in all types of burns. It can heal the wound and reduce burn comorbidities such as pain and itch and it can sedate burned patients.

## REFERENCES

- Hosseinimehr SJ, Khorasani G, Azadbakht M, Zamani P, Ghasemi M, Ahmadi A. Effect of aloe cream versus silver sulfadiazine for healing burn wounds in rats. *Acta Dermatovenerol Croat* 2010;18:2-7.
- Miller AC, Rashid RM, Falzon L, Elamin EM, Zehtabchi S. Silver sulfadiazine for the treatment of partial-thickness burns and venous stasis ulcers. *J Am Acad Dermatol* 2012;66:e159-65.
- Beheshti A, Shafigh Y, Zangivand AA, Samiee-Rad F, Hassanzadeh G, Shafigh N. Comparison of topical sucralfate and silver sulfadiazine cream in second degree burns in rats. *Adv Clin Exp Med* 2013;22:481-7.
- Yaman I, Durmus A, Ceribasi S, Yaman M. Effects of *Nigella sativa* and silver sulfadiazine on burn wound healing in rats. *Vet Med* 2010;55:619-24.
- Kwa KA, Pijpe A, Middelkoop E, van Baar ME, Niemeijer AS, Breederveld RS, et al. Comparing doxepin cream to oral antihistamines for the treatment of itch in burn patients: A multi-center triple-blind randomized controlled trial. *Burns Open* 2019;3:135-40.
- Kuipers HC, Bremer M, Braem L, Goemanne AS, Middelkoop E, Van Loey NE. Itch in burn areas after skin transplantation: Patient characteristics, influencing factors and therapy. *Acta Dermatovenerol* 2015;95:451-6.
- Demling R, De Santi L. Topical doxepin significantly decreases itching and erythema in the healed burn wound compared to oral antihistamines. *J Burn Care Rehabil* 2002;23:S81.
- Goutos I, Eldardiri M, Khan AA, Dziejewski P, Richardson PM. Comparative evaluation of antipruritic protocols in acute burns. The emerging value of gabapentin in the treatment of burns pruritus. *J Burn Care Res* 2010;31:57-63.
- Zabihi M, Hajhashemi V, Minaiyan M, Talebi A. Evaluation of the central and peripheral effects of doxepin on carrageenan-induced inflammatory paw edema in rat. *Res Pharm Sci* 2017;12:337.
- Zabihi M, Hajhashemi V, Talebi A, Minaiyan M. Evaluation of central and peripheral effects of doxepin on acetic acid-induced colitis in rat and the involved mechanisms. *EXCLI J* 2017;16:414.
- Zimmermann M. Ethical guidelines for investigations of experimental pain in conscious animals. *Pain* 1983;16:109-10.
- Bhattacharya S. Principles and practice of Burn care. *Indian J Plast Surg* 2009;42:275.
- Sadeghi-Bazargani H, Mohammadi R. Epidemiology of burns in Iran during the last decade (2000-2010): Review of literature and methodological considerations. *Burns* 2012;38:319-29.
- Hajhashemi V, Minaiyan M, Banafshe HR, Mesdaghinia A, Abed A. The anti-inflammatory effects of venlafaxine in the rat model of carrageenan-induced paw edema. *Iran J Basic Med Sci* 2015;18:654-8.
- Hajhashemi V, Sadeghi H, Minaiyan M, Movahedian A, Talebi A. The role of central mechanisms in the anti-inflammatory effect of amitriptyline on carrageenan-induced paw edema in rats. *Clinics (Sao Paulo)* 2010;65:1183-7.
- Yanai K. [(11)C] Doxepin binding to histamine H1 receptors in living human brain: Reproducibility during attentive waking and circadian rhythm. *Front Syst Neurosci* 2012;6:45.
- Shimamura T, Shiroishi M, Weyand S, Tsujimoto H, Winter G, Katritch V, et al. Structure of the human histamine H1 receptor complex with doxepin. *Nature* 2011;475:65.
- Janssen DG, Caniato RN, Verster JC, Baune BT. A psychoneuroimmunological review on cytokines involved in antidepressant treatment response. *Hum Psychopharmacol Clin Exp* 2010;25:201-15.
- Cheng B, Liu HW, Fu XB. Update on pruritic mechanisms of hypertrophic scars in postburn patients: The potential role of opioids and their receptors. *J Burn Care Res* 2011;32:e118-25.
- Ahuja RB, Gupta GK. A four arm, double blind, randomized and placebo controlled study of pregabalin in the management of post-burn pruritus. *Burns* 2013;39:24-9.
- Harper D, Young A, McNaught CE. The physiology of wound healing. *Surgery (Oxford)* 2014;32:445-50.
- Enoch S, Leaper DJ. Basic science of wound healing. *Surgery (Oxford)* 2008;26:31-7.
- McCleane G. Topical application of doxepin hydrochloride, capsaicin and a combination of both produces analgesia in chronic human neuropathic pain: A randomized, double-blind, placebo-controlled study. *Br J Clin Pharmacol* 2000;49:574-9.