



# Percutaneous extraction of big kidney stone without fragmentation: The novel technique in percutaneous nephrolithotomy (EN BLOC PCNL)

Hormoz Karami<sup>a</sup>, Serajoddin Vahidi<sup>a</sup>, Saeid Abouie<sup>b</sup>, Hamed Gholizadeh<sup>a,\*</sup>

<sup>a</sup> Department of Urology, Shahid Sadoughi University of YAZD, Iran

<sup>b</sup> Intern of Medical Sciences, Shahid Sadoughi University of YAZD, Iran

## ARTICLE INFO

### Keywords:

Percutaneous nephrolithotomy  
Nephrolithiasis  
Renal stone  
Kidney calculi

## ABSTRACT

PCNL is gold standard treatment of pelvis stone more than 2 cm. Since 1970 that PCNL was introduced, multiple methods including mini PCNL, Lap assisted PCNL etc. were used to increase the efficacy and decrease the complications of PCNL in different patients. We describe a new method of PCNL for the first time for extracting 7 cm renal stone without fragmentation, and we called it EN BLOC PCNL. Our technique had no complication and caused lower operative time.

## Introduction

PCNL is gold standard treatment of stone that indicated. Since PCNL was introduced, multiple methods were used to increase the efficacy and decrease the complications of PCNL. We describe a novel technique for extracting 7 cm renal stone without fragmentation, and we called it EN BLOC PCNL.

## Case report

A 60 years old man because of right flank pain had undergone sonography & CT scan & KUB that showed 2 stone with cumulative diameters of about 70 mm in middle calyx & pelvic that was referred to our center to performance PCNL, (Fig. 1). In PMS's patient (past medical history) had history of PCNL as a result of calcium oxalate monohydrate stone with the size of 30 mm in right kidney, also the patient who had undergone treatment had COPD. In CT scan, the stone with 1100 Hounsfield unit with severe hydronephrosis was seen, also it was reported the parenchymal was thin. Patient with BMI 19 (body mass index), after initial evaluation & necessary testing check without contraindication was a candidate to PCNL. In this center, PCNL was performed with C-ARM fluoroscope in prone position also with 26 rigid cystoscope & pneumatic lithoclast. As the result of continuous headache in the previous surgery, the patient did not let us do spinal anesthesia, so that the general anesthesia was done. After the insertion 6fr ureteral stent in lithotomy position, the patient was repositioned to prone & all the steps for finding access in middle calyx were done & amplatz sheath

30fr was inserted. We tended to fragment the stone but unfortunately pneumatic lithoclast got failed. Ultimately, we had to choose one of the following steps; i.e., either to cancel the operation or to perform open nephrolithotomy.

Because the stone was highly available from that tract & could be touched with finger due to low BMI of the patient. With extending 3.5 cm incision on the skin and muscles the stone was touchable then with help of the finger, incision of parenchyma slightly expanded. The stone in middle calyx was quite palpable due to thin parenchymal & also the stone in pelvis was floating, so that the stone was taken by ring forceps with guide of C-ARM FLUOROSCOPE & it was rotated in the direction of the lowest diameters, then it was taken out by ring forceps<sup>1</sup>; (Fig. 2).

The tubeless operation was carried out because of absence of an obvious bleeding & also without residual stone (we check with C-ARM FLUOROSCOPE). Only the skin was closed up using 3-0 nylon threats with far & near stitch technique. The good point which took 4 minutes beginning from the stone getting out to the end. The follow-up in the lab data such as: hemoglobin, electrolytes, after the operation, we did not observe a tangible change. Ultimately, the patient with ciprofloxacin 500 mg BD (bis in die) was discharged from the hospital, & after 7 days, ureteral stent (Fig. 3) & Foley catheter came out & also in the fourteenth day, it was removed suture without any complication such as wound infection required blood transfusion & lack of urine leak. The composition of stone was calcium oxalate monohydrate. In follow-up we evaluated the patient with IVP (intravenous pyelogram) after 3 months, that showed, the structure of calyx & secretion was normal;<sup>2</sup>

\* Corresponding author. Resident of Urology, Department of Urology, Shahid Sadoughi University of Medical Sciences, Bahonar Square, Yazd, Iran.  
E-mail address: [dr.hamed.urology@gmail.com](mailto:dr.hamed.urology@gmail.com) (H. Gholizadeh).

<https://doi.org/10.1016/j.eucr.2021.101749>

Received 31 May 2021; Received in revised form 6 June 2021; Accepted 8 June 2021

Available online 13 June 2021

2214-4420/© 2021 The Authors.

Published by Elsevier Inc.

This is an open access article under the CC BY-NC-ND license

(<http://creativecommons.org/licenses/by-nc-nd/4.0/>).

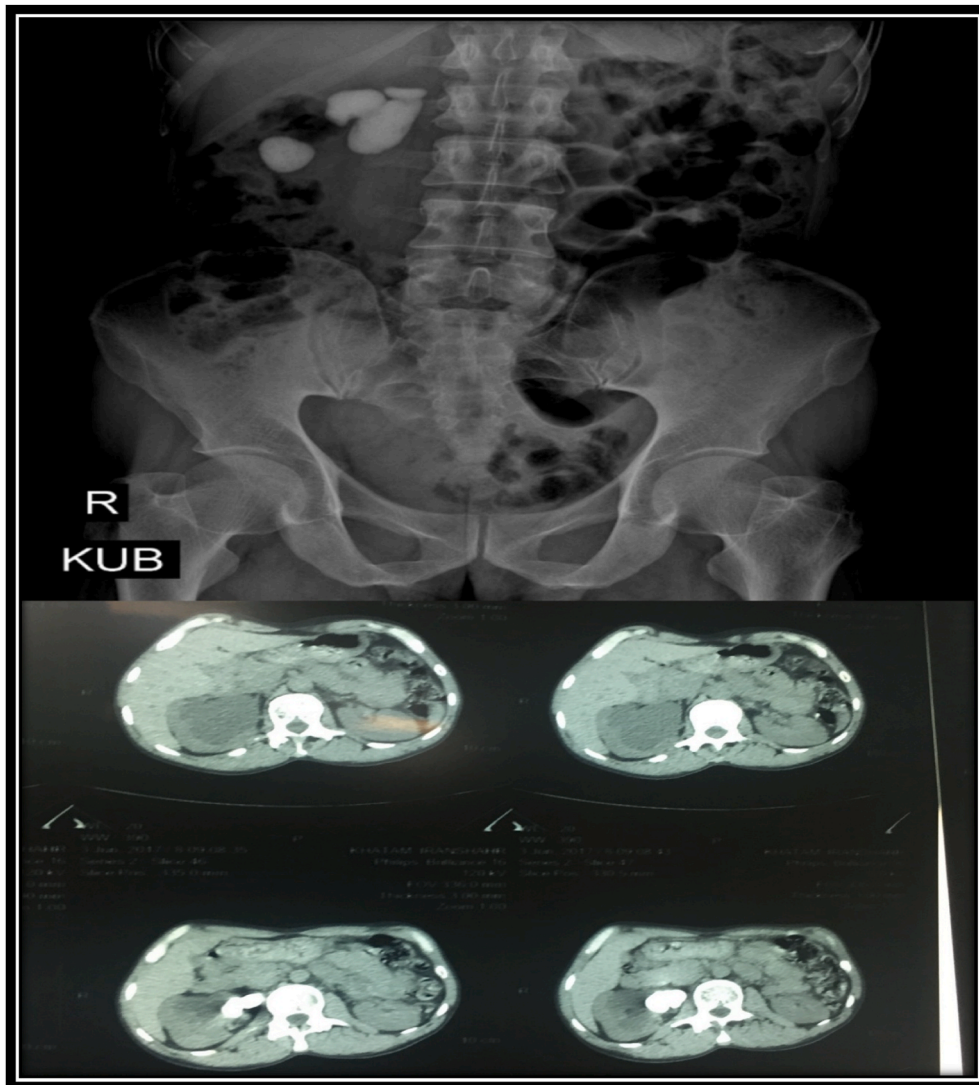


Fig. 1. CTscan & x-ray image of the KUB that showed stone in right kidney.

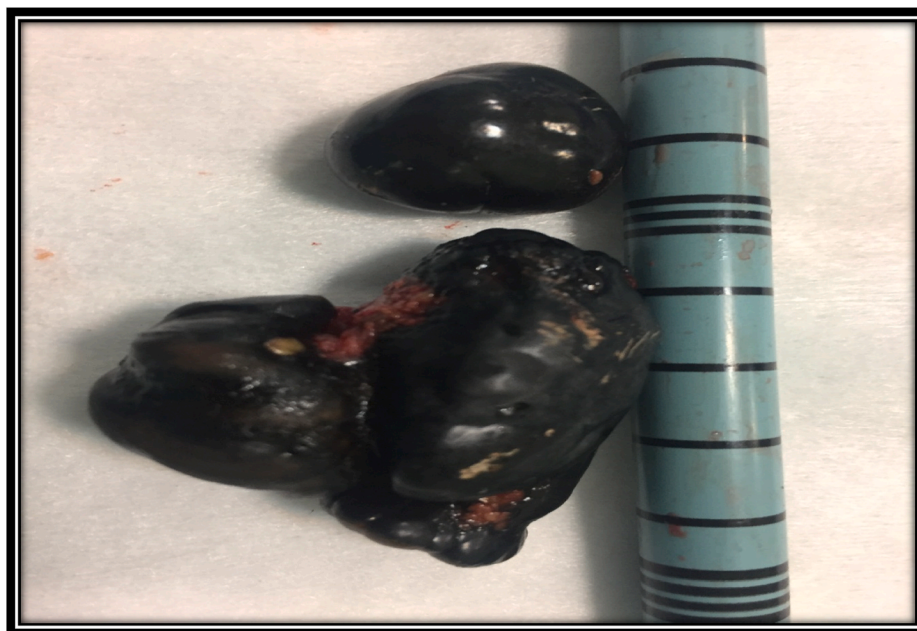


Fig. 2. 2 stone that cumulative diameters of about 70 mm were removed.

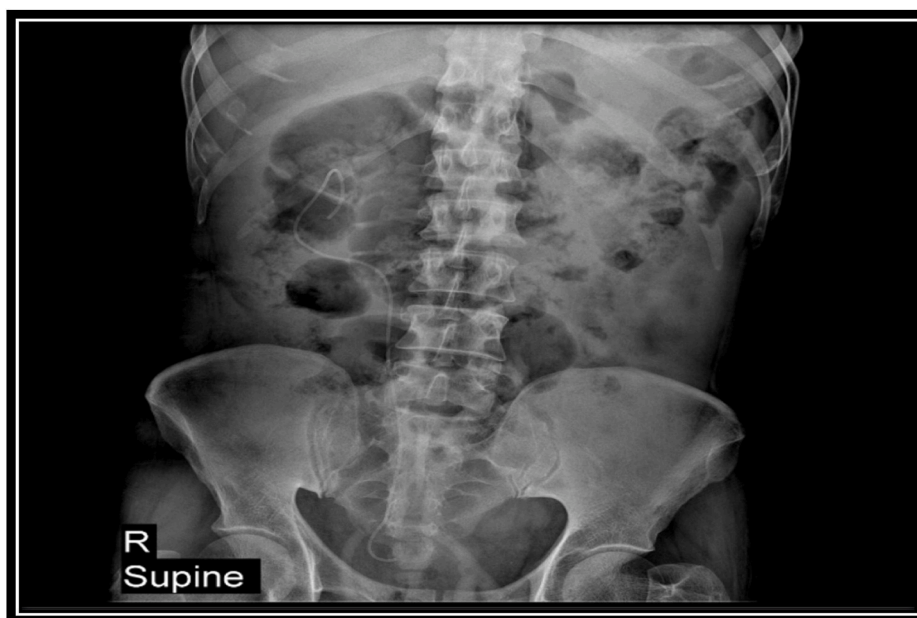


Fig. 3. Post-op x-ray image of the KUB.

## Discussion

The goal of PCNL surgery is to remove kidney and ureteral stones percutaneously. PCNL has replaced open renal surgery in most cases of large or complex calculi. Following the introduction of PCNL in the 1970s, much research has been done in order to improve this technique and reduce postoperative pain, complications and hospital stay. The standard PCNL has several difficulties such as the need for several accesses in the case of larger stones, more steps in surgery and longer operation time that can be a problem especially in patients with underlying disorders who cannot tolerate operations with long durations. As for the complications of this method, transfusion, fever, injury to nearby organs, possible renal failure and hyponatremia are among the most important. Postoperative hyponatremia caused by the use of

irrigation fluid has adverse neurological outcomes including coma and seizure.<sup>3,4</sup>; In this case report we introduced a novel PCNL technique, the EN BLOC PCNL, we removed stone without fragmentation; however, it was never used in kidney stone removal in stone greater than access sheet diameters. Size, location & material of stone, are affecting on time to take out the stone despite in this method does not affect. According to Guohua zeng' metaanalysis the maximum & minimum time duration of the operation ranged from 31 to 106.6 minutes.<sup>5</sup>; Our operation time for the EN BLOC method in this patient was 30 minutes, that was lower than any other methods, & hospital stay for this patient was 2 days. We were able to reduce operation time & anesthesia duration & absence of some of PCNL surgical tools like pneumatic lithoclast. Regarding the pre- and post-operative Para clinical tests, research indicated a decrease in hemoglobin and sodium levels and an increase in creatinine levels after

PCNL surgeries. Likewise, in this case we did not have more hemorrhage that required transfusion. We used a little irrigation fluid (100 cc physiological serum), that was the reason for absence of hyponatremia in this case. Ultimately, in this case with dense stone (Hounsfield 1000) in the kidney with thin parenchymal, we were able to remove with EN BLOC method without hyponatremia, blood transfusion & without any complications.

Recommendation: This method is not recommended for all patients that candidate PCNL but the patients who are candidate PCNL with dense stone & rather single with thin parenchyma are applicable to perform the operation in a limited time.

## References

1. Castaneda-Zuniga WR, Clayman R, Smith A, Rusnak B, Herrera M, Amplatz A. Nephrostolithotomy: percutaneous techniques for urinary calculus removal. *for urinary calculus removal*. 2002;167(2):849–853.
2. Ralph V. Clayman, Vilanur Surya, Wilfrido R. Castaneda Zuniga, et al Percutaneous nephrolithotomy with mazzariellocaprini forceps. *The, J Urol*.1983, jun;129(6):1213-1215.
3. Chou CH, Chau T, Yang SS, Lin SH. Acute hyponatremia and renal failure following percutaneous nephrolithotomy. *Clin Nephrol*. 2003;59(3):237–238.
4. Lauritz JB. Hyponatremia coma following percutaneous nephrolithotomy. *Anesthesia and intensive care*. 1986;14(2):210–211.
5. Zhu Wei, Liu Yang, Liu Luhao, et al. Minimally invasive versus standard percutaneous nephrolithotomy: a meta-analysis. *Urolithiasis*. 2015. <https://doi.org/10.1007/s00240-015-0808-y>.