

Giant Juvenile Fibroadenoma Presenting in a 15-year-old Pregnant Woman: a Case Report

Mansour Moghimi, MD¹, Hamid Reza Soltani, MD², Mojtaba Babaei Zarch, MD^{3*}

1. Department of Pathology, Shahid Sadoughi University of Medical Sciences, Yazd, Iran

2. General Physician, Scientific Society of Medicine, Yazd branch, Islamic Azad University, Yazd, Iran

3. Student Research Committee, Shahid Sadoughi University of Medical Sciences, Yazd, Iran.

*Corresponding author: Mojtaba Babaei Zarch, MD. Shahid Sadoughi Hospital, Shahid Sadoughi University of Medical Sciences, Yazd, Iran. Email: mojtaba.babaei72@yahoo.com.

Received: 13 August 2016

Accepted: 10 December 2016

Abstract

Fibroadenoma is the most common benign mass of breast in females 20-50 years of age. Juvenile fibroadenoma accounts for only 4% of total fibroadenomas. Moreover, the incidence of giant juvenile fibroadenoma is found to be only 0.5% of all fibroadenomas. A 15-year-old woman at the 12th week of gestation was referred to the Shahid Sadoughi Hospital, Yazd, Iran because of a mass in the right breast from one year ago. On Physical examination and imaging, a large mass was found in her right breast. Fine needle aspiration biopsy reported fibroadenoma. Mass enucleation and breast reconstruction were performed. Pathologic examination confirmed a giant fibroadenoma. No serious complications were reported during one-month follow up. The most highlighted point of this presentation was giant size of juvenile fibroadenoma in a pregnant woman. This case report shows that large breast tumors in the adolescent age group can be benign and breast-conserving surgery should be considered in such cases.

Keywords: Breast, Fibroadenoma, Pregnancy, Surgery

Introduction

Fibroadenoma (FA) is the most common benign mass of breast in females 20-50 years of age (1, 2). FA originates from epithelium and connective tissue of hyperplasic terminal duct units. Giant fibroadenoma (GF) is defined as a tumor that grows more than 5cm in size or 500gr in weight or involves 4/5 of mammary gland (2). GF is the most common cause of asymmetric and unilateral macromastia in adolescent accounting for 2-10% of all breast FA (3). A wide spectrum lesions such as inflammatory process and other benign lesions including fibrocystic disease, hamartoma, and lipoma may be considered as differential diagnosis of GF (3). This is a case of giant juvenile fibroadenoma in a pregnant woman who underwent mass enucleation and breast reconstruction.

Case report

A 15-year-old pregnant woman in the 14th week of gestation was referred to Shahid Sadoughi Hospital, Yazd, Iran. She noted a mass in the right breast from one year ago that had developed more rapidly during pregnancy. On physical examination, right breast was significantly larger than left breast. The mass was mobile and the patient had no systemic signs and symptoms. The left breast and both axillae were normal. Fine needle aspiration biopsy (FNAB) reported fibroadenoma. After two days, the patient underwent surgery and an encapsulated giant mass was removed through a small incision in the right upper quadrant of breast. Afterward, we noted a small mass in the right upper quadrant of right breast that was completely separated from another mass.

In macroscopic evaluations, the large mass was encapsulated 22×19×9cm in size and 2125gr in weight with gray color, nodular surface and semi-solid consistency (Fig.1). In microscopic findings of large mass, ducts and stromal ducts covered with cuboids to columnar epithelial and myoepithelial cells were seen and few mitotic cells were reported. Periductal stroma was infiltrated by chronic inflammatory cells (Fig.2). The small mass contained small ducts that were covered by cuboidal epithelial cells with round shape nuclear and vacuolated cytoplasm. Collection of ducts seemed pseudo-lobular formations. Stroma was not dense. A few lymphocytes were present in stroma. The final diagnosis was giant juvenile fibroadenoma. Two days after surgery drain was removed and patient had good general condition.

Discussion

Fibroadenoma is the most common benign breast tumor in teenagers. Physical examination is very important in early detection of fibroadenoma. Mainly, observation is the standard treatment (4). Giant fibroadenoma is a type of fibroadenoma with prevalence of less than 4% in breast lesions among female adolescent patients (5). It mostly occurs between 10-18 years and is often very large at the first presentation. Its etiology is unknown till now but it seems that end-organ hypersensitivity to normal level of gonadal hormones is the main cause of GF (6).

The typical presentation of a juvenile fibroadenoma is an enlarged painless mass. The involved breast is usually with prominent superficial veins. The areola may appear enlarged (4, 7). It has been found as an asymptomatic, mobile and well circumscribed mass that could be associated with inflammatory signs (4, 6). Its differential diagnosis includes cystosarcoma phylloides, lipoma, circumscribed fibrocystic mass, giant hamartoma and various carcinomas (8).

Diagnostic methods especially radiological evaluation is controversial. Mammography is not recommended for pediatrics. Moreover, it is not routinely suggested for GF because of poor quality images due to dense fibro-glandular breast in GF cases and mammography may be normal (6, 7, 9). In ultrasound evaluation, GF has been found as oval, round or macro lobulated well-circumscribed hypo/isoechoic and homogeneous lesion that makes ultrasonography the best imaging modality for diagnosis of GF. In Doppler ultrasonography, the lesion is avascular or with minimal internal vascularity in 67% of cases (10).

Excisional biopsy is not suggested but FNA can help surgeons to differentiate other possible diagnosis such as phylloides tumors that have similar ultrasound features with GF (11). Because of large size of GFs, mass enucleation and breast reconstruction is the suggested surgical procedure (12).

In this presentation, our case was referred by typical clinical manifestations and fine needle aspiration confirmed FA. Mass enucleation and breast reconstruction was done and it seems that mastopexy and other supplemental procedure is not requirement.

Conclusion

According to current report, surgery is recommended for GF because of its rapid growing. Exact physical examination and imaging help the physicians in early detection of GFs. This case report shows that large breast tumors in the adolescent age group can be benign and breast-conserving surgery should be considered in such cases.

Acknowledgment

Special thanks with Sepanta Gostar Novin research group who helped the authors to report this case.

Conflict of interest

Authors have no conflict of interest.

References

1. Lo MN, Nibid A, Farello G, Gabriele A, Giuliani M. Giant fibroadenoma of the breast in an adolescent: a case report. *Ann Ital Chir* 2001;73(6):631-4.
2. Alagaratnam T, Ng W, Leung E. Giant fibroadenomas of the breast in an oriental community. *J R Coll Surg Edinb* 1995;40(3):161-2.
3. Gobbi D, Dall'Igna P, Alaggio R, Nitti D, Cecchetto G. Giant fibroadenoma of the breast in adolescents: report of 2 cases. *J Pediatr Surg*. 2009; 44(2):e39-e41.
4. Simmons RM, Cance WG, Iacicca MV. A Giant Juvenile Fibroadenoma in a 12-Year-Old Girl: A Case for Breast Conservation. *Breast J* 2000;6(6):418-20
5. Chang DS, McGrath MH. Management of benign tumors of the adolescent breast. *Plast Reconstr Surg* 2007; 120(1):13e-9e.
6. Agarwal P, Sparnon AL. Benign breast lesions in adolescent girls: an overview with a case report. *Pediatr Surg Int* 2005;21(5):381-2.
7. Dolmans GH, Hoogbergen MM, van Rappard JH. Giant fibroadenoma of one breast: Immediate bilateral reconstruction. *J Plast Reconstr Aesthet Surg* 2007; 60(10):1156-7.
8. Weinzwieg N, Botts J, Marcus E. Giant hamartoma of the breast. *Plast Reconstr Surg* 2001; 107(5):1216-20.
9. De Silva NK, Brandt ML. Disorders of the breast in children and adolescents, part 2: breast masses. *J Pediatr Adolesc Gynsecol* 2006; 19(6):415-8.
10. Kronemer KA, Rhee K, Siegel MJ, Sievert L, Hildebolt CF. Gray scale sonography of breast masses in adolescent girls. *J Ultrasound Med* 2001;20(5):491-6.
11. Pacinda SJ, Ramzy I. Fine-needle aspiration of breast masses: a review of its role in diagnosis and management in adolescent patients. *J Adolesc Health* 1998; 23(1):3-6.
12. Beier J, Jaeger K, Horch R. Reduction mammoplasty for benign phyllodes tumour in an adolescent female—A 13-year follow up. *Breast* 2006; 15(4):550-3.

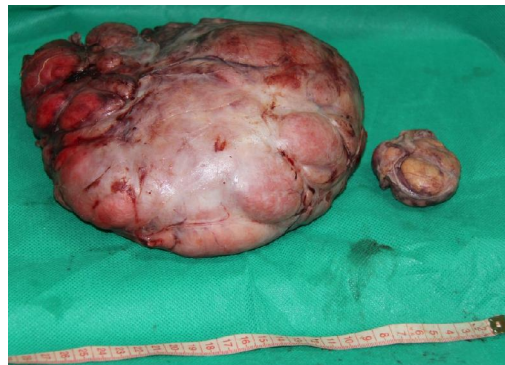

Figure 1. In macroscopic evaluation, large tumor had gray color and nodular surface with semi solid consistency.

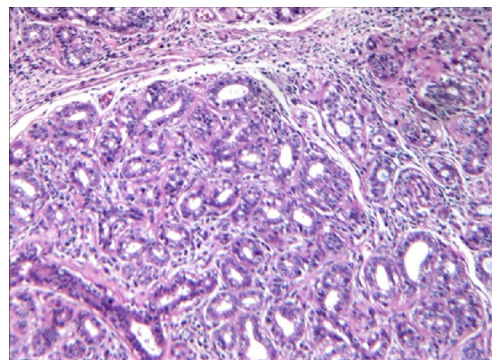


Figure 2. H&E stain X10. In microscopic examination of large tumor, ducts and stromal ducts covered with cuboids to columnar epithelial. Myoepithelial cells were see